

Immunohistochemical Detection of HCV in Nerves and Muscles of Patients with HCV Associated Peripheral Neuropathy and Myositis

Layla K.Younis¹, Farouk M Talaat², Ahmed H Deif², Mohamed F Borei², Seham M Abdel Reheim³, Doa H El Salmawy²

Departments of: ¹ Pathology, ² Neuropsychiatry, ³ Tropical Medicine, Faculty of Medicin . Alexandria University. Egypt.

Background : Chronic hepatitis C Virus (HCV) infection may be associated with numerous extrahepatic manifestations, such as mixed cryoglobulinaemia, membranoproliferative glomerulonephritis, sicca syndrome. Cryoglobulinaemia (CG) is a condition characterized by the presence of serum proteins that reversibly precipitate in the cold. The objective of the present work was to study the histopathological changes in neuromuscular biopsies in patients with HCV associated peripheral neuropathy, or myopathy; with and without cryoglobulinemia, and to assess the presence of HCV in nerve and muscle tissues of those patients which might clarify some pathogenetic mechanisms for neuropathy, and myopathy associated with HCV.

Methods : The study was conducted on 17 cases of HCV infected patients with peripheral neuropathy and myositis. All patients were subjected to thorough laboratory investigations, neurological examination, electrophysiologic studies including nerve conduction, and needle EMG studies.

Results : Histopathological examination of nerve biopsies showed features of vasculitis in 2/10 cases, interstitial inflammatory infiltrates in 5/10. Muscle biopsies showed intense inflammatory reaction, degenerative changes in the muscles of 3/10 cases diagnosed as myositis.

Immunohistochemical results, showed in nerve biopsies, 7/10 cases with positive reaction for HCV with nuclear and perinuclear staining.. Two patients showed positive reaction in the epineural, and endoneural blood vessels and a negative reaction in nerve bundles, while in five patients, reaction was only positive in the nerve bundles.

In muscle biopsies, 7/10 cases showed positive reaction for HCV in the nuclei of the muscle fibers, including the cases presented with myositis.

Conclusion : The presence of HCV particles in nerve and muscle biopsies of patients with peripheral neuropathy suggests a virus triggered immune mediated mechanism.

Correspondence:

*Dr. Layla Kamal Younis
Department of Pathology
Faculty of Medicine
Alexandria University, Egypt
l_k_younis@yahoo.com*

Introduction

Chronic hepatitis C virus (HCV) infection may be associated with numerous extrahepatic manifestations, such as mixed cryoglobulinaemia, membranoproliferative glomerulonephritis, Sicca syndrome.⁽¹⁾ Peripheral neuropathy (PN) may also be associated with HCV infection and it is usually related to mixed cryoglobulinaemia.⁽²⁾ Before HCV was discovered, PN was known to be associated with type II or type III, rather than type I cryoglobulinaemia.⁽²⁾ However, the presence of a PN in a patient positive for HCV may be due to other causes, including PN without mixed cryoglobulinaemia.⁽³⁾

Cryoglobulinaemia (CG) is a condition characterized by the presence of serum proteins that reversibly precipitate in the cold. According to the molecular composition, cryoglobulins are classified into three types: type I, isolated monoclonal Ig; type II, monoclonal IgM rheumatoid factor (RF) associated with a polyclonal component; type III, polyclonal Ig. Types II and III are classically referred to as "mixed cryoglobulinaemia".⁽²⁾

CG may be idiopathic (essential mixed cryoglobulinaemia, EMC) or secondary to other diseases, such as lymphoproliferative disorders, collagen diseases, and chronic infections. It has been reported that 46%–54% of patients with chronic hepatitis C virus (HCV) infection show detectable CG, although most of them do not have CG related symptoms.^(4,5)

According to different reports, peripheral neuropathy (PN) is present in variable proportions in patients with symptomatic CG, related or not to HCV.^(6,7) PN usually occurs in type II and type III CG, rather than type I, and may clinically present as a mononeuropathy, multiple mononeuropathy, or polyneuropathy.^(8,9) Most mixed cryoglobulinaemia described as "essential" is now known to be related to HCV infection.⁽¹⁰⁾

However, some HCV+ patients with PN and persistent negativity for CG have been reported.^(11,12) Only isolated reports are available regarding neuromuscular biopsies in CG- patients disclosing mainly axonal damage without demonstration of a vasculitic process.^(11,12,13)

Hence, the objective of the present work was to study the histopathological changes in neuromuscular biopsies of patients with HCV associated neuropathy, or myositis with and without cryoglobulinemia, and to assess the presence of HCV in nerve and muscle tissues of

those patients which might clarify some mechanisms in the pathogenesis of neuropathy and myopathy associated with HCV.

Methods

The study comprised consecutive seventeen HCV-infected patients with peripheral neuropathy, and myositis that were referred to the department of neurology, faculty of medicine, Alexandria University, Egypt. Patients with other causes of peripheral neuropathy and myositis were excluded from the study (diabetes, collagen vascular disease, cancer, liver failure and renal failure, etc.). Ten normal control subjects matched for age and sex with no evidence of hepatitis c infection were included.

All patients were subjected to thorough neurological examination with particular attention to the peripheral nervous system, complete abdominal examination, electrophysiologic studies including nerve conduction, and needle EMG studies.

Laboratory investigations comprised: HCV antibodies detected by third generation ELISA test in serum, PCR for HCV-RNA, Immunofixation electrophoresis to detect polyclonal IgG and monoclonal IgM cryoglobulins, Hepatitis B surface antigen and anti HB IgG to exclude mixed infections. Hepatic function tests, renal function tests, fasting blood sugar. Stool and urine were performed to exclude shistosomal infection.

For histopathologic study, sural nerve biopsy was performed, and muscle biopsy was taken from the medial head of the gastrocnemius muscle. The muscle biopsy was slightly stretched over wooden tongue depressor for 2 minutes then placed in 10% formaldehyde fixative for 24 hours then processed and embedded in paraffin blocks.

H&E stained section were performed for histopathological examination and 5 microns sections placed on silanized slides were prepared for immunostaining.

Immunostaining procedure for Hepatic C virus

Sections were incubated in xylene, rehydrated by grades of alcohol, immersed in distilled water, then immersed in boiled citrate buffer (pH 6.1) in microwave (1400W) for 5 minutes. An ultraviolet detection system antipolyvalent HRP horse radish peroxidase / AEC were used. All sections were placed in hydrogen peroxide for 15 minutes, incubated overnight, at 4 °C with the ready to use monoclonal antibody to hepatitis C virus TORJ1-22 (Biogenex). Slides were then incubated with biotinylated goat

antipolyvalent for 25 minutes, at room temperature, and then incubated in streptavidin peroxidase for 25 minutes. Between incubations, sections were washed two times in phosphate buffered saline for 5 minutes each. The colour reaction was developed by using AEC (3 amino-9-ethyl carbazole) giving red colour to the positive reaction. Mayer's haematoxylin was used as counterstain. The positive staining is nuclear or perinuclear.

The antibody TORDJI-22 is reactive with the nonstructural region of HCV (NS3-NS4). No cross reactivity with hepatitis B virus surface antigen or hepatitis A virus was detected by ELISA. Some reactivity is occasionally observed with an unknown component of human bile.

Negative and positive control sections were included in each run.

Results

The study comprised 2 groups of 27 cases, group I is composed of 17 patients infected with HCV and had neurological manifestations, and group II composed of 10 normal men acting as control.

Group I were all males with age ranged from 22-50 y (38±8.4), while group II were also males with their age ranged from 27-50 y (37.2 ± 7.8)

Laboratory investigations

1. All patients in group I had positive serology for HCV antibodies, and positive PCR for HCV-RNA.

All the other lab findings are summarized in table (1)

2. Essential mixed cryoglobulinemia type II (EMC)

There were 2 patients in group I (12 %) having positive EMC.

Neurological manifestations in Group I

(I) Fourteen patients suffered from signs and symptoms of peripheral neuropathy, those patients were further divided into:

(i) Three patients (21.4 %) had only distal sensory neuropathy

(ii) Two patients (14.2 %) had multiple mononeuritis (mononeuritis multiplex) manifested by asymmetrical weakness, upper limbs were more involved than lower limbs

iii- Nine patients (64.2 %) had symmetrical sensory motor polyneuropathy with prominent motor affection with prominent motor affection evidenced by wasting and weakness of the affected lower limbs. The weakness was proximal rather than distal. Sensory manifestations were in the form of glove and stocking hypoesthesia, one of the patients had bilateral motor neuron facial nerve affection.

Table (1). Comparison between group I and group II as regard laboratory investigation. * t test considered significant when P value < 0.05.

Lab Study	Group I		Group II		t test	P value
	Range	Mean ±SD	Range	Mean ±SD		
I. CBC						
HB%	74-90	83.25±5.12	85-96	90.2±3.58	3.83	0.001*
WBC c/cmm	3000-8300	5616±1556.7	4000-5840	4862±578.1	1.918	0.666
Platelet count/cmm (x10 ³)	200-350	273.4±46.832	210-380	283±32.503	0.509	0.615
II. Hepatic Function						
AST	20-100	58.3±21.3	17-22	20±2.24	7.9	0.000*
ALT	34-110	63.2±20.9	19-25	22±2.11	8.71	0.000*
Prothrombin time sec.	12.5-19	14.6±1.69	11-12.5	11.9±0.61	6.3	0.000*
Serum Albumin	3.5-4.7	4.095±0.367	3.9-5.1	4.6±0.46	3.250	0.003*
III. Renal function						
Urea	20-35	28.15±4.6	22-35	28.8±4.4	0.367	0.71
Creatinine	0.7-1.3	0.99±0.18	0.7-1.3	0.97±0.18	0.273	0.78
IV. Fasting BS	70-105	84.3±10.9	70-106	82.2±9.4	0.519	0.437
V. ESR						
First hour	18-40	27.7±7.2	10-20	15.4±3.5	6.3	0.000*
Second hour	30-62	44.3±10.3	17-40	29.2±7.04	4.715	0.000*

(II). Three patients presented clinically with myositis. They had myalgia, proximal symmetrical weakness, and difficulty in climbing upstairs or rising from low seats, dysphagia, and difficulty to hold neck erect. Those patients showed good response to oral corticosteroids 60mg/day with pain improvement. The diagnosis was supported by electrophysiologic and pathologic examination.

Electrophysiological findings in patients with peripheral neuropathy

The fourteen patients had abnormal nerve conduction:

1. Three patients with axonal sensory peripheral neuropathy showed marked diminished amplitude of sensory nerve potential for both ulnar and median nerves with absent sural nerve response. included in this pattern are the two patients with the cryoglobulinaemia.
2. Two patients with mononeuritis multiplex showed marked assymmetry between responses of both right and left sides. In both patients upper limbs were more affected than lower limbs. One patient showed multifocal conduction block evidenced by severe diminution of proximal amplitude compared to distal one. This patient had right lower motor neuron facial lesion.

Nine patients with sensory motor demyelinating peripheral neuropathy (Guillan Barre- like) manifested by delayed distal latencies and F waves latencies with marked reduction of the nerve conduction with moderate decrease in the compound muscle action potential (CMAP) amplitude. The sensory response also showed delayed distal latencies and decrease in the amplitude.

Electromyogram studies showed abnormalities consistent with peripheral neurogenic lesions in 11/17(65%) patients, and myopathic pattern in 3cases (18%) while it was normal in 3/7cases with axonal sensory polyneuropathy.

Histopathological examination: Twenty biopsy specimens from nerve and muscle of ten patients with peripheral neuropathies or myositis were performed.

Sural nerve biopsy showed in general axonal degeneration; two patients disclosed features of vasculitis in the form of inflammatory infiltrates in the blood vessel wall, while five cases showed inflammatory infiltrates in the nerve bundles, one of those 5 cases showed thickened blood vessel wall, and hyperplasia of

smooth muscle of the tunica media. Two cases showed non specific changes.

In muscles biopsies three cases (presented clinically by myositis) showed histological evidences of myositis, in the form of degenerated muscle fibers, nuclear changes, interstitial inflammatory infiltrates and fibrosis (Fig 1), while the rest of the cases showed non specific changes. No histological evidence of vasculopathy detected in any of the muscle biopsies.

Immunohistochemical findings

Liver biopsy from patient with HCV infection was used as a positive control (Fig. 2),

In nerves biopsies, seven cases (70%) showed positive reaction for HCV with nuclear and perinuclear staining in both the nerve and muscles sections, while reaction was negative in three cases.

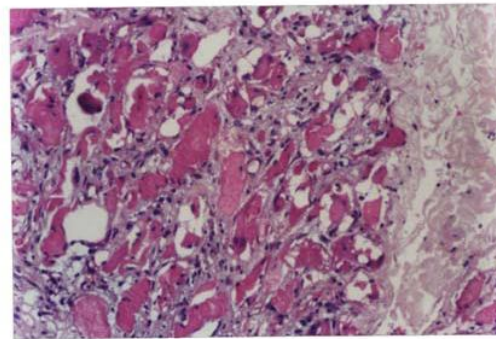


Fig (1). A case of myositis showing degenerated muscle fibers, nuclear changes, interstitial inflammatory infiltrates and fibrosis (H&E stain 40X).

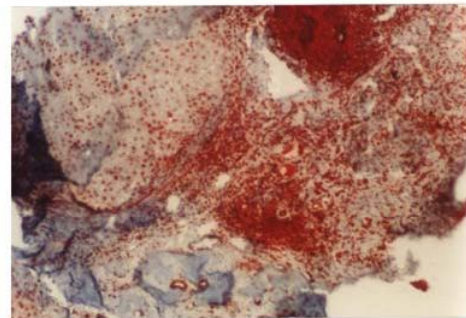


Fig (2). Liver biopsy from a patient with HCV infection showing positive nuclear reaction in the hepatocytes, portal inflammatory cells (immunostaining by streptavidin biotin method) 20 X.

Two nerve specimens (20%) showed positive reaction in the epineurial and endoneurial blood vessel wall and a negative reaction in nerve bundles, i.e neuropathy in these two cases was probably due to vasculitis (Fig. 3,4). While five patients (50%) showed positive reaction in the nerve bundles and negative reaction in the vessels wall (Fig 5).

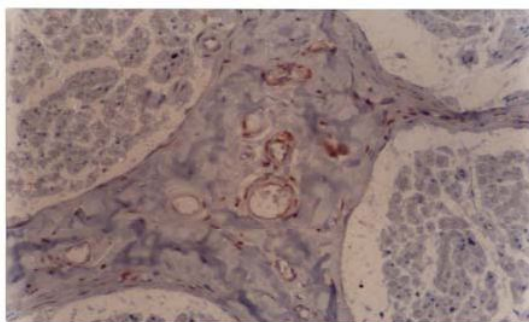


Fig (3). A case of PN showing positive immunostaining of HCV in the blood vessels wall and negative reaction in nerve bundles 20 X

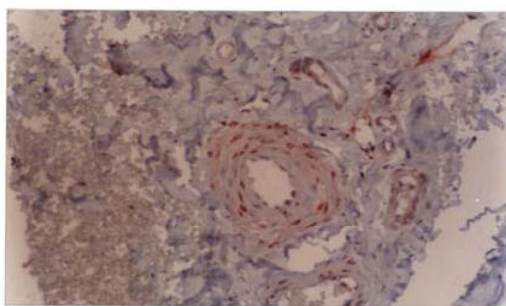


Fig (4). Another case of PN showing positive reaction in smooth muscle cells of tunica media.40X

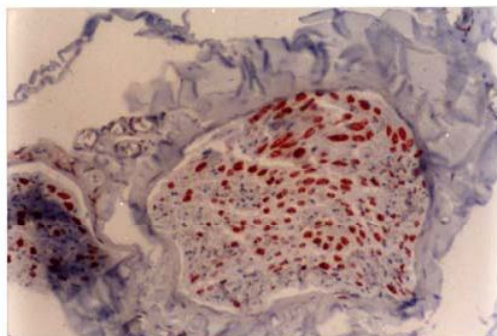


Fig (5). Nerve trunk showing strong nuclear immunostaining for HCV . 40X

In muscle biopsies, seven cases (70%) showed positive reaction for HCV in the nuclei of the muscle fibers (Fig 5), including the cases presented with myositis (Fig 6). No positive reaction was detected in the blood vessels.

The expression of staining varied from case to case. In general, cases with intense inflammatory reaction showed focal and mild intensity of staining (Fig 7). Those with minimal inflammatory response showed diffuse and intense staining pattern.

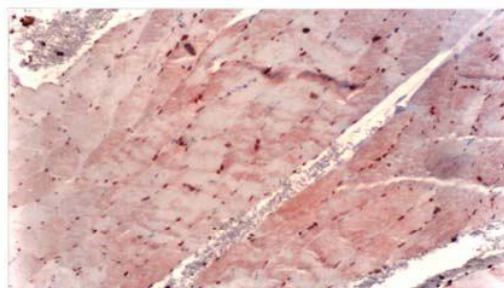


Fig (6). Muscle bundles showing diffuse and strong nuclear immunostaining of HCV in skeletal muscle fibers. 20X

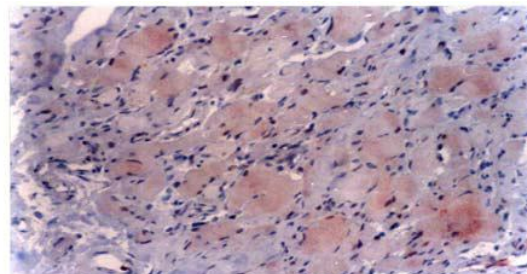


Fig (7). Muscle biopsy in a case of myositis showing focal mild nuclear immunopositivity in muscle fibers 20 X.

Discussion

The association between HCV and PN is well established^(3,9). Savant et al⁽¹⁴⁾ reported that peripheral neuropathy was the most common clinical syndrome involving their patients with HCV infection, and although cryoglobulins were less prevalent and significant. The underlying mechanisms were possibly viral invasion or dysimmune mechanism^(13,14)

In the present study, most of the cases were clinically diagnosed as symmetric sensory motor polyneuropathy (64.2%) followed by distal sensory neuropathy (21.4%), and mononeuritis multiplex (14.2%); Several previous studies characterized PN involvement in HCV CG+

patients as a subacute distal, motor sensory polyneuropathy^(9,10,15) A sensory motor PN has been found in up to 9% of patients chronically infected with HCV, and the prevalence rise up to 30% in CG+ patients.⁽³⁾ Our results are different from those of Authier *et al*⁽¹⁶⁾ who had distal peripheral neuropathy in 83% of his patients, and from those of Olidove *et al*⁽¹¹⁾ who reported mononeuritis multiplex in 3/4 cases. An asymmetrical sensory impairment has often been highlighted.⁽⁸⁾ Mono and multiple mononeuritis have been also reported^(17, 18)

The association between HCV infection and CG is well established. Detectable CG is present in about 50% of HCV patients although most of them do not have CG related symptoms.⁽⁴⁾ Peripheral neuropathy associated with HCV is mainly characterized by axonal damage and it was usually reported in association with CG. Only isolated reports are available regarding neuromuscular biopsies in CG- patients disclosing mainly axonal damage without demonstration of a vasculitic process.^(11,12)

In our study only 2 /17 (12%) cases were positive for CG, and 15/17 cases were CG-. Nerve biopsies revealed axonal degeneration in all the cases with PN, vasculitis in 2/10 cases who had CG +, the rest of the specimens did not show any features of vasculitis. However, inflammatory infiltrates were seen in nerve bundles of 5/10 cases while 3/10 cases did not show any inflammatory reaction..

In muscle biopsies, the 3 cases of myositis showed inflammatory reaction in the muscle fibers, degenerative changes, but no features of vasculitis are detected in any of the muscle biopsy specimens. In the literature, inflammatory lesions varying from epineurial vasculitis to perivascular inflammatory infiltrates have been reported.^(13, 18,19) We did not found vasculitis in CG- cases, however, pathological evidence of a vasculitic process was detected in HCV CG+ and in HCV CG- patients by Nemni *et al*.⁽¹³⁾ The mechanism of vasculitis in CG+ patients was explained by the ability of CG to activate the complement pathway and cause vasculitis.⁽¹³⁾

In the present work, we detected by immunohistochemical technique HCV in 7/10 (70%) cases nerve and muscle tissues of our patients. This result is in agreement with the results of Emanuelle *et al*⁽¹⁹⁾ who reported positive immune staining in the nerves mainly in the endoneurium, and epineurium, in five out of

nine patients. De Martino *et al*⁽²⁰⁾ assessed the presence of RNA in nerve of 10/15 patients with HCV and PN (10/11 without mixed cryoglobulinemia, and 4/5 with cryoglobulinemia).

Fukuoka *et al*⁽²¹⁾ reported 3 patients with myositis after infection with HCV, and detected HCV-RNA genome in one patients, and HCV immune reactivity in another patient out of the 3 cases. These findings suggested that HCV infection was related to the pathogenesis in some cases of myositis.

In contrast to the present study, Ferri *et al*⁽²²⁾ did not detect HCV virus particles in nerve biopsies by immunofluorescence which supported the hypothesis of indirect damage to the nerve perhaps by cryoglobulins or inflammatory cells.

The variable histological features and immunohistochemical results suggest different pathogenetic mechanisms for neuropathy or myositis.

It was postulated that nerve damage is secondary to epineurial vessels changes caused by occlusion or vasculitis induced by longstanding cryoglobulin precipitation with complement fixation and RF deposition. The vasculitis or vascular occlusion causes fascicular ischaemia that results in axonal degeneration.⁽⁸⁾ It has also been supposed that CG or immunocomplexes, or both, contribute to the generation of microvascular, but not vasculitic, changes in epineurial and endoneurial capillaries, whereas only T cell dependent mechanism account for the epineurial inflammation.⁽²³⁾ A recent study demonstrated a role for cellular immunity in the pathogenesis of HCV- CG vasculitis; they found high expression of T helper cytokines (Interferon γ and TNF α) in vasculitic nerve lesions.⁽²⁴⁾

Another view, supposed that HCV may have a direct role in the pathogenesis of neuropathy; it could induce nerve damage by a direct cytopathic effect or by an immunomediated mechanism such as immune complex induced changes of the epineurial vessels. This hypothesis seems to be supported by the finding of HCV RNA in five nerve biopsy specimens by RT-PCR *in situ* and could explain the neurological involvement in CG- patients.⁽²⁰⁾

Against the direct cytopathic role of the virus is the detection of positive strand genomic HCV RNA in nerve samples showing vasculitis, while negative stranded replicative RNA was not detected^(16,25)

Conclusions

The detection of HCV in nerve and muscle tissue in patients with HCV neuropathy whether associated with CG or not indicate that HCV neuropathy results from virus triggered immune mediated mechanisms. Further studies are needed to clarify the relevance of the insitu HCV induced chronic stimulation of the immune system.

References

- Gumber SC, Chopra S. Hepatitis C: a multifaceted disease. *Ann Intern Med* 1995; 123:615-620.
- Brouet JC, Clauvel JP, Danon F, Klein M, Seligmann M. Biological and clinical significance of cryoglobulins. *Am J Med* 1974; 57:775-788.
- Cacoub P, Renou C, Rosenthal E. Extrahepatic manifestation of hepatitis C virus infection in 321 patients. *Medicine* 2000; 79: 47-56.
- Adinolfi LE, Utili R, Attanasio V. Epidemiology, clinical spectrum and prognostic value of mixed cryoglobulinemia in hepatitis C virus patients: a prospective study. *It J Gastroenterol* 1996; 28: 1-9.
- Lunel F, Musset L, Cacoub P. Cryoglobulinemia in chronic liver disease: role of hepatitis C virus and liver damage. *Gastroenterology* 1994; 106: 1291-300.
- Ferri C, Greco F, Longombardo G. Antibodies to hepatitis C virus in patients with mixed cryoglobulinemia. *Arthritis Rheum* 1991; 34: 1606-10.
- Zaltron S, Puoti M, Liberini P. High prevalence of peripheral neuropathy in hepatitis C virus infected patients with symptomatic and asymptomatic cryoglobulinemia. *It J Gastroenterol Hepatol* 1998; 30:391-5.
- Nemni R, Corbo M, Fazio R. Cryoglobulinemic neuropathy: a clinical morphologic and immunocytochemical study of 8 cases. *Brain* 1988; 111:541-52.
- Santoro L, Manganelli F, Brian C, Gianini F, Vitelli E, MBeghi E. Prevalence and characteristics of peripheral neuropathy in hepatitis C virus population. *Journal of neurology, neurosurgery and Psychiatry* 2006; 77: 66-626-629.
- Vital C, Deminiere C, Lageuny A. Peripheral neuropathy with essential mixed cryoglobulinemia: biopsies from five cases. *Acta neuropathol* 1988; 75: 605-10.
- Lidov O, Cacoub P, Maisonneuve T, Servan J, Leger JM. Hepatitis C virus infection with peripheral neuropathy is not always associated with cryoglobulinemia. *Ann Rheum Dis* 2001; 60:290-292 .
- Paoletti V, Donnarumma L. HC virus infection. Peripheral neuropathy without cryoglobulinemia in patients with hepatitis. *Panminerva Med* 2000; 42:175-8.
- Nemni R,LSanvito, Quattrini A, Canal N. Peripheral neuropathy in hepatitis c virus infection with and without cryoglobulinemia. *Journal of neurology neurosurgery and psychiatry* 2003;74:1267-71
- Savant M, John M, Herbert L. Extrahepatic manifestations of infection with hepatitis C virus. *Clinics in liver disease*2001; 5:123-151.
- Gemignani F, Melli, Inglese C. Cryoglobulinemia is a frequent cause of peripheral neuropathy in undiagnosed referred patients. *J peripher nerv syst* 2002;7:59-64.
- Authier F-J, Bassez G, payan C, Belec L. Detection of genomic viral RNA in nerve and muscle of patients with HCV neuropathy. *Neurology* 2003; 60:808-812.
- David WS, Peine C, Schlesinger P, Smith SA. Nonsystemic Vasculitis neuropathy multiplex, cryoglobulinemia and hepatitis C. *Muscle nerve* 1996; 19: 1596-602.
- Poynard T, CocubP. Peripheral neuropathy in patients with chronic hepatitis C (HCV) . *J Viral hepatology* 2002; 9:295-303.
- Emmuelle A, Jean L, Lucile M. peripheral neuropathy associated with essential mixed cryoglobulinemia: a role for hepatitis C virus infection. *J Neurol Neurosurg Psychiat* 1996; 60: 661-66
- De Martino L, Sampolo S, Tucci C, Di Iorio G, Viral RNA in nerve tissue of patients with hepatitis C infection and peripheral neuropathy. *Muscle nerve* 2003; 27(1):102-4.
- Fukuoka I, Tsuruta Y, Yamada T. Inclusion body myositis associated with hepatitis C virus infection *Igaku* 2001; 92: 370-6.

22. Ferri C, Marzo E, Longombardo G. Association between hepatitis C virus and mixed cryoglobulinemia. *Clin Exp Rheumatol* 1999; 9: 621-624.
23. Bonetti B, Rizatto N. T- cell mediated epidermal vasculitis and humoral mediated microangiopathy in cryoglobulinemic neuropathy. *J Neuroimmunol* 1997; 73:145-54.
24. Saadoun D, Bieche I, Asselah T, Viddaud M, Cacoub P. Involvement of chemokines and type 1 cytokines in the pathogenesis of hepatitis C virus associated mixed cryoglobulinemia vasculitis neuropathy. *Arthritis & Rheumatism* 2005; 52 (9): 2917-25.
25. Poyan L, Gullivin L, Authier F. Detection of genomic but not replicative hepatitis C virus RNA in nerve and muscle of patients with HCV associated neuropathy. *Am Acad Neurol* 2000; 54:385-9.