

Case Report

Ventriculoperitoneal Shunt with Communicating Peritoneal & Subcutaneous Pseudocysts Formation

Dr Al-Duraibi Sharifa

Abstract

A case of cerebrospinal fluid (CSF) pseudocysts in a patient with a ventriculoperitoneal (VP) shunt is reported to describe acute unusual location of development of pseudocyst.

In the setting of a VP shunt, the frequency of abdominal CSF pseudocyst formation is approximately 4.5%, often being precipitated by a recent inflammatory / infective process or recent surgery. Larger pseudocysts tend to be sterile, whereas smaller or multiloculated pseudocysts are more often infected. Computed tomography (CT) and ultrasound (US) has characteristic findings.

This is an uncommon presentation of VP shunt with no evidence of infection. The objective of this case report is to create awareness about imaging findings of complications of VP shunt at an unusual location.

Key words:

Cerebrospinal fluid pseudocyst; Computed tomography; Ultrasound; Ventriculoperitoneal shunt.

Correspondence:

Dr. Al-Duraibi Sharifa

Radiology Department

King Khalid University Hospital

Cell No: 0505173364,

Email: dr.s.alduraibi@gmail.com

Case Report

A 14-year-old boy presented with sudden onset of headache and abdominal pain. He was known to have congenital hydrocephalus, with two ventriculoperitoneal (VP) shunts revisions for obstructive hydrocephalus, the most recent shunt was being placed 2 days prior to the presentation. The abdominal examination showed a small soft mass in the umbilical region. It was non-tender and not fixed to the underlying skin. Plain abdominal radiographs on admission were non-conclusive. A contrast enhanced CT of the abdomen and pelvis revealed a well-defined, non-enhancing water density cystic collection at the right paraumbilical region. It measured 5 × 5 × 4 cm (Figs-1). The small bright dots within the cyst and in the vicinity as well as at the abdominal wall were identified as VP shunt in cross-section. A diagnosis of Pseudocyst due to complication of VP shunt was made due to typical CT signs. Another adjacent abdominal wall cystic lesion is seen in addition to multiple lobulated pseudocysts through the right chest and abdominal wall encasing the same subcutaneous and peritoneal cysts which aspirated and confirmed as pseudocysts due to VP shunting.

Discussion

Placement of a ventriculoperitoneal shunt is an established procedure for treatment of hydrocephalus, however, complications can occur.

The most common causes of shunt malfunction are catheter obstruction and infection. The incidence of ventriculoperitoneal shunt related abdominal complications has been reported to be from 5% to 47%.⁽¹⁾ The most common distal ventriculoperitoneal shunt complications include shunt infection, subcutaneous collection of CSF, peritoneal pseudocyst, bowel perforation, intestinal volvulus, mesenteric pseudotumor, migration of the catheter into the pleural cavity and heart, and development of an incision hernia.⁽⁸⁾

Peritoneal CSF pseudocysts are a rare but important complication of VP shunt surgery, with a reported incidence ranges from less than 1.0% to 4.5%. Most of the reported cases are of pediatric age group or early adolescence.⁽⁶⁾

The most common presentation of an abdominal CSF pseudocyst in children is elevated intracranial pressure and abdominal pain, whereas local abdominal signs, such as abdominal pain, distention, nausea, or vomiting, predominate in adults.⁽⁶⁾

The time from the last shunting procedure to the development of an abdominal pseudocyst ranges from 3 weeks to 5 years. However there are case reports of CSF pseudocyst formation with interval ranged from 5 days to 25 months from the last VP shunting operation. The mean period between the last ventriculoperitoneal shunting operation and abdominopelvic CT was 11 months (range, 1 week to 115 months), and the mean number of ventriculoperitoneal shunting operations undergone was 1.4 (range, 1–6).⁽⁸⁾

CSF pseudocysts have a variable appearance and may impair CSF absorption. Bowel obstruction is an infrequent complication of CSF. Larger CSF pseudocysts tend to be noninfectious, whereas cysts that are smaller or multiloculated may develop infection.

The CSF pseudocyst can either move freely within the peritoneal cavity or adhere to loops of bowel, the serosal surface of solid organs, or the parietal peritoneum.

Sonography and CT can accurately localize abdominal fluid collections; differentiation of ascites from the aforementioned cystic lesions may not be possible. Therefore, fine-needle aspiration of the localized CSF collections under sonographic or CT guidance should be performed to increase the diagnostic yield. Culture of the tip of the peritoneal catheter was reported to be more sensitive than culture of the CSF.

Once the shunt tip is removed, the pseudocyst gradually collapses because the wall is composed of fibrous tissue without an epithelial lining.

The formation of a CSF pseudocyst is a poor prognostic sign for the usefulness of the peritoneal cavity for shunting. Although previous abdominal pseudocyst formation and peritonitis are not contraindications to subsequent peritoneal shunting in some reports, the CSF had to be diverted to other cavities because of either recurrence of the cysts or failure of the peritoneum to absorb fluid.

Fig. 1-a – Contrast enhanced abdominopelvic CT scan axial images shows 5× 4 x 5 cm well defined non-enhancing cystic area in the right paraumbilical regional along with internal shunt catheters (arrows).

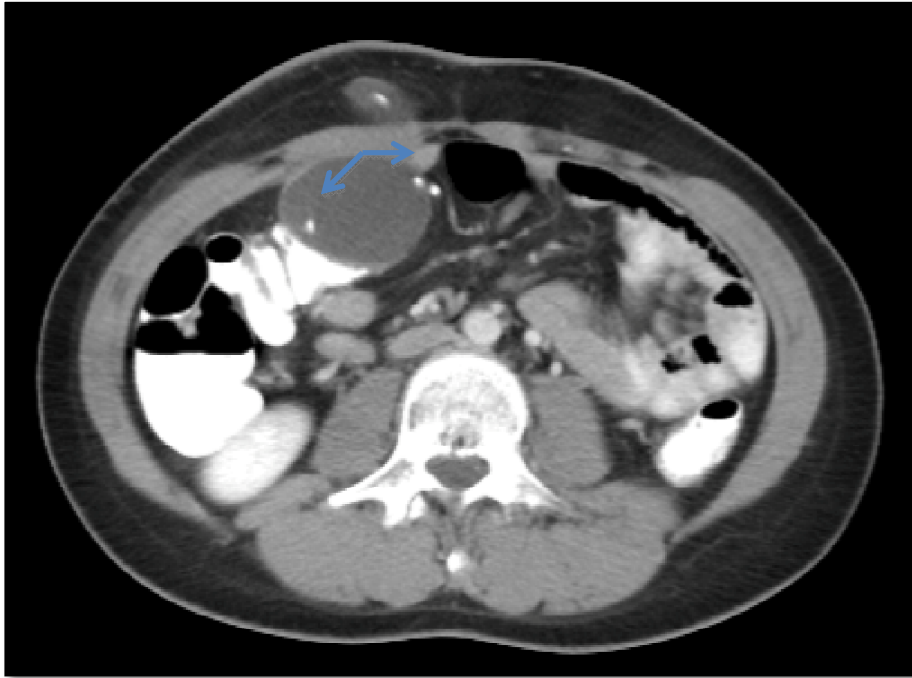


Fig 1b-Contrast enhanced abdominopelvic CT scan sagittal reformate image show peritoneal and abdominal wall pseudocysts.

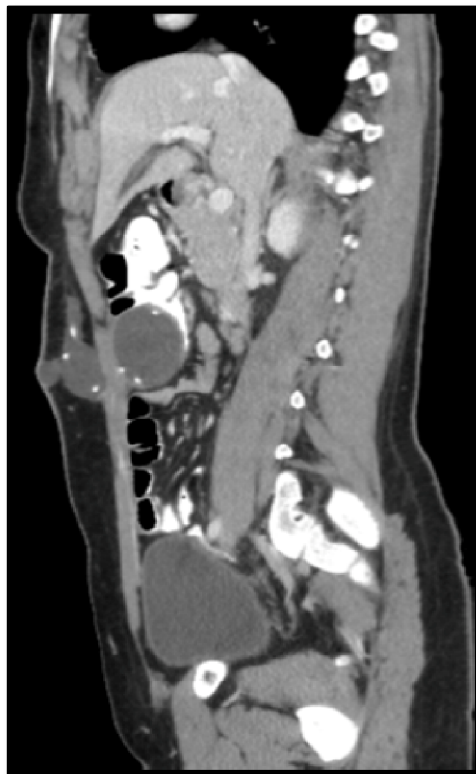

Fig. 2 Contrast enhanced abdominopelvic CT scan axial images shows two shunt catheter tubes (arrows).

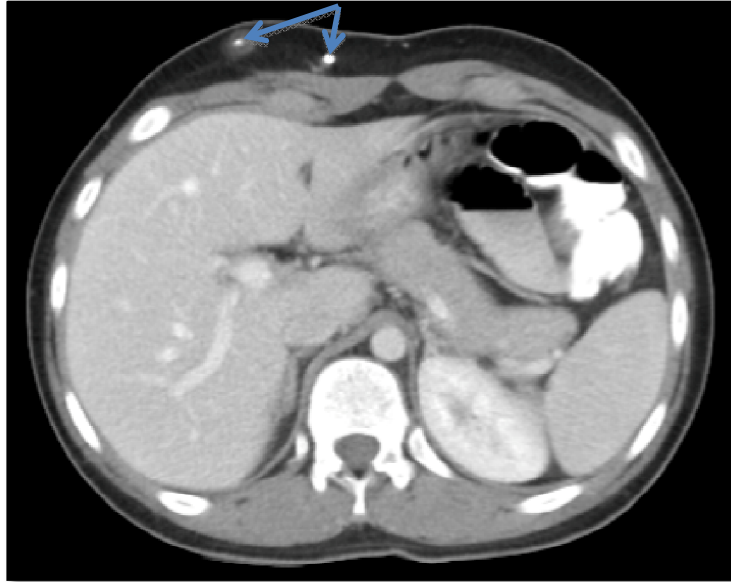
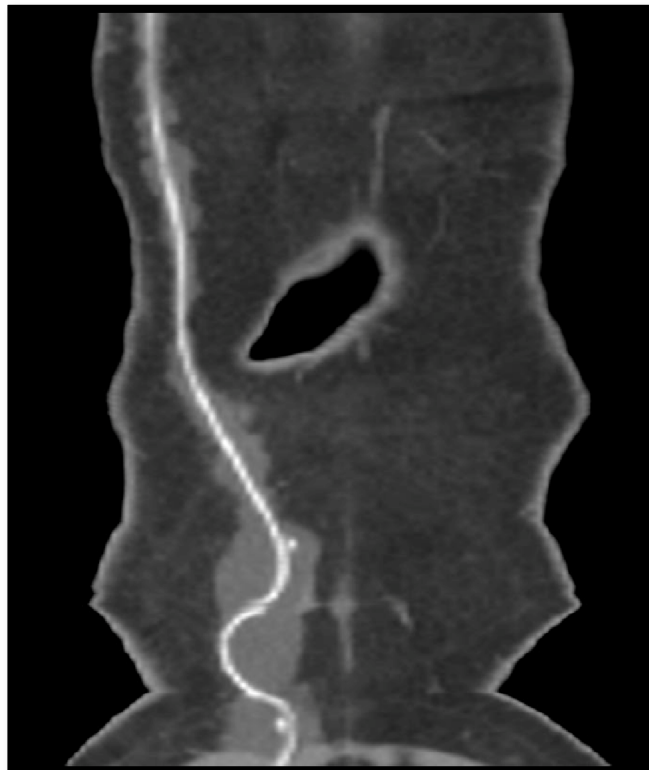


Fig. 3 Contrast-enhanced abdominopelvic CT scan coronal reformate image shows the course of the catheter surrounded by the pseudocysts formation.



References

1. Esposito C, Porreca A, Gangemi M, et al. The use of laparoscopy in the diagnosis and treatment of abdominal complications of ventriculoperitoneal shunts in children. *Pediatr Surg Int* 1998; 13:352–354.
2. Bal RK, Singh P, Harjai MM. Intestinal volvulus – a rare complication of ventriculoperitoneal shunt. *Pediatr Surg Int* 1999; 15(8): 577-578.
3. Paddon AJ, Horton D. Knotting of distal ventriculoperitoneal shunt tubing. *Clin radiol* 2000; 55:1-3.
4. Acharya R, Ramachandran CS, Singh S. Laparoscopic management of abdominal complications in ventriculoperitoneal shunt surgery. *J Laparoendosc Adv Surg Tech* 2001; 11:167-170.
5. Wani AA, Ramzan A, Wani MA. Protrusion of a peritoneal catheter through the umbilicus: an unusual complication of a ventriculoperitoneal shunt. *Pediatr Surg Int* 2002; 18:171-172.
6. Ramon Pathi, Michael Sage, John Slavotinek and Ahmad Hanieh. Abdominal cerebrospinal fluid pseudocyst. *Australasian Radiology* (2004) 48, 61–63.
7. Martinez Hernandez-Magro P, Román CB, S-enz EV, Zavala MJ. Colonic perforation as a complication of ventriculoperitoneal shunt: a case report. *Tech Coloproctol* 2006; 10:353-355
8. Jae-Joon Chung, Jeong-Sik Yu, Joo Hee Kim, Se Jin Nam¹ and Myeong-Jin Kim. Intraabdominal Complications Secondary to Ventriculoperitoneal Shunts: CT Findings and Review of the Literature. *J AJR* November 2009 vol. 193 no. 5 1311-1317.