

Role of heme oxygenase-1, cytokines, and vascular endothelial growth factor in murine *Schistosoma mansoni*

Etimad A. Huwait¹,
Maryam A. AL-Ghamdi¹,
Maivel H. Ghattas²,
Adel R. Hinnis³,
Dalia A. Abo El-Maaty⁴,
Dina M. Abo-Elmatty⁵,
Asmaa R. Abdel-Hamed⁵

¹Department of Biochemistry, Science College, King Abdulaziz University, Saudi Arabia,

²Department of Medical Biochemistry, Faculty of Medicine, Port Said University, Port Said, Egypt, ³Department of Pathology, Faculty of Medicine, Suez Canal University, Ismailia, Egypt, ⁴Department of Medical Parasitology, Faculty of Medicine, Zagazig University, Zagazig, Egypt, ⁵Department of Biochemistry, Faculty of Pharmacy, Suez Canal University, Ismailia, Egypt

Address for correspondence:

Asmaa R. Abdel-Hamed, Lecturer of Biochemistry, Faculty of Pharmacy, Suez Canal University, 41522 Ismailia, Egypt.
E-mail: asmaa.ramdan@pharm.suez.edu.eg

WEBSITE: ijhs.org.sa

ISSN: 1658-3639

PUBLISHER: Qassim University

Introduction

Schistosomes are members of a medically important group of parasitic helminthes that contribute to severe morbidity and mortality among people in 74 tropical and subtropical developing nations.^[1] *Schistosoma mansoni* infection is considered a worldwide problem that affects large geographic areas in several countries situated in Africa, Madagascar, the Middle East, parts of South America, and the Caribbean region.^[2] In Egypt, the prevalence of *S. mansoni* in five endemic governorates in the lower Egypt ranged from 17.5% to 42.9% with an average of 36.4%.^[3]

Heme oxygenase (HO) is the rate-limiting enzyme in the conversion of heme into biliverdin, carbon monoxide (CO), and free iron (Fe²⁺).^[4] Three HO isoforms have been identified; they are inducible HO-1, also known as heat shock protein

ABSTRACT

Objectives: Among tropical diseases, schistosomiasis caused by *Schistosoma mansoni* is the second major cause of morbidity and mortality worldwide. Inflammation was considered as an adverse event that contributes to the pathology associated with schistosomiasis. Heme oxygenase-1 (HO-1) and vascular endothelial growth factor (VEGF) have been implicated in the process of angiogenesis. The current study aimed to evaluate the effect of *S. mansoni* infection on HO-1 gene expression, IL-4, IL-12, and VEGF to address the role of these factors in the pathogenesis of schistosomiasis.

Methods: Thirty mice divided equally into three groups comprised a non-infected control group and two *S. mansoni*-infected groups. Infected animals were studied at 8 and 12 weeks post-infection. Serum IL-4, IL-12, and VEGF were measured. HO-1 mRNA was detected by RT-PCR of liver homogenates and HO activity was assessed as percentage of carboxy hemoglobin.

Results: *S. mansoni*-infected mice showed a progressive increase in serum IL-4 and VEGF and decrease in IL-12 levels. In addition, HO-1 expression and activity were increased in infected mice compared to control group with the maximum increase at egg deposition stage.

Conclusion: Our results suggested that the body response to acute stage of *S. mansoni* infection by elevating the expression of the stress gene HO-1 and that VEGF may serve as a new indicator of progression of *S. mansoni* associated angiogenesis which regulates granuloma and/or fibrosis development in the liver of infected mice. Understanding the role of HO-1 and VEGF in pathogenesis of *S. mansoni* may provide a new pharmacological target.

Keywords: HO-1 gene expression, IL-12, IL-4, *Schistosoma mansoni*, vascular endothelial growth factor

32, constitutively expressed HO-2 and a related but less well characterized HO-3.^[5] Under physiologic conditions, HO-1 expression is relatively low. Upregulation of HO-1 may be among the most critical cytoprotective mechanisms that are activated during cellular stress and inflammation.^[4] HO-1 is thought to play a key role as an anti-inflammatory gene.^[4,5] Moreover, HO-1 has been implicated in the process of angiogenesis.^[6,7]

Endothelial cells play a fundamental role in the pathogenesis of schistosomiasis as well as in granuloma formation.^[8] In addition, *in vitro* studies have revealed that soluble schistosomal egg antigens upregulate vascular endothelial growth factor (VEGF) and angiogenesis.^[9] Since angiogenesis appears to be a key factor for new connective tissue synthesis, assay of VEGF levels in schistosomiasis seemed to be appropriate.

Cytokines play a crucial role in the evolution and regulation of schistosoma-induced immunopathology. T lymphocytes are a major source of cytokines. These cells bear antigen specific receptors on their cell surface to allow recognition of foreign pathogens. There are two main subsets of T lymphocytes, CD4 and CD8. T lymphocytes expressing CD4 are also known as helper T cells, and these are considered the most prolific cytokine producers. T helper (Th) cells can be further subdivided into Th1 and Th2, and the cytokines they produce are known as Th1-type cytokines and Th2-type cytokines. Th1-type cytokines tend to produce the pro-inflammatory responses responsible for killing intracellular parasites and for perpetuating autoimmune responses. Excessive pro-inflammatory responses can lead to uncontrolled tissue damage, so a counteract mechanism is required which include Th2-type cytokines. In excess, Th2 responses will counteract the Th1 mediated microbicidal action.^[10] The immune response to schistosomal antigens manifest a striking shift from a moderate Th1 to a robust Th2-dominant response.^[11] Interleukin (IL)-4 plays a key role in the Th2-associated immune response, on the other hand, IL-12 induces Th1- response.^[12]

The aim of the current study was to evaluate the effect of schistosomiasis caused by murine *S. mansoni* on HO-1 gene expression, IL-4, IL-12, and VEGF to address the role of these factors in granuloma formation.

Material and Methods

Animals and experimental design

S. mansoni cercariae (Egyptian strain) were obtained from infected *Biomphalaria alexandrina* snails which were purchased from Theodor Bilharz Research Institute (TBRI), Giza, Egypt and used for mice infection using tail immersion technique by 100 cercariae/mouse.^[13] The study includes thirty males, Swiss albino mice aged 8–12 weeks old and weighting 20–25 g. Mice were housed in an animal house at Faculty of Pharmacy, Suez Canal University and were allowed to free access of food and water. Experimental animals were kept and used in accordance with the Guide for the Care and Use of Laboratory Animals (National Research Council, 2011). All experimental protocols were approved by the Ethics Committee at the Faculty of Pharmacy, Suez Canal University (Ismailia, Egypt) (code # 201906RA1). The study was continued for 6 months at the time from September 2019 to February 2020.

Mice were divided into three groups of ten mice each. The three groups comprised non-infected mice (control group) and two *S. mansoni*-infected groups (100 cercariae/mouse). Infected animals were studied at 8th (acute phase) and 12th (chronic phase) weeks post-infection.^[14] At the end of the study, serum was separated for determination of IL-4, IL-12, and VEGF. Mice were sacrificed and part of the liver was removed, rapidly frozen in liquid nitrogen and used for detection of HO-1 mRNA and HO-1 activity and another part was fixed in 10% formalin

for histopathological examination and immunohistochemical staining of VEGF.

Cytokines and VEGF determination

IL-4, IL-12, and VEGF were measured in the serum of control and infected mice groups by enzyme-linked immunosorbant assay (ELISA) technique according to the manufacturer's instructions.

RT-PCR for detection of HO-1 mRNA

Total RNA was isolated from liver tissues using RNA extraction kit (Qiagen, Germany). Concentration of the extracted RNA was measured by NanoDrop ND-1000 (NanoDrop Tech., Wilmington, USA). Specific primers for mice HO-1 cDNA fragment: primer 1: 5'-AAC ACA AAG ACC AGA GTC CCT CAC-3', primer 2: 5'-CAA GAG AAG AGA GCC AGG CAA GAT-3' and G3PDH primers sense: 5'-CTG CCA TTT GCA GTG GCA AAG TGG-3', antisense: 5'-TTG TCA TGG ATG ACC TTG GCC AGG-3' were used.^[15] PCR was performed using one step RT-PCR kit (Qiagen, Germany). Cycling conditions for amplifying RT products were as follows: 95°C, 1 min; 57°C, 1 min; 72°C, 1 min, for 28 cycles, and then extended at 72°C for another 5 min.^[15] After amplification, PCR products were electrophoresed on 1.2% agarose gel, stained with ethidium bromide and visualized under UV light. The PCR products were then quantitated by using a quantitation kit (Promega Corporation, Madison, WI, USA). The results were expressed as µg/mg wet tissue.

Assay of HO activity

Carboxy hemoglobin (COHb) percentage of the arterial blood was performed gasometrically by Blood Gas Analyzer (Bayer Rapid lab 865, USA) according to the method described by Hampson *et al.*^[16]

Histology and immunohistochemistry

The part of liver tissue fixed in 10% formalin was used. Representative tissue biopsies were selected, processed, and embedded in paraffin blocks. Five tissue sections (4 µm thick) were cut; each was 250 µm away from the preceding section to avoid assessment of the same granuloma. Tissue sections were deparaffinized and stained for Hematoxylin and Eosin (H&E) and Masson Trichrome.^[17] For each mouse, the hepatic histopathological findings were recorded and the degree of portal fibrosis was assessed.

Paraffin sections (5 µm thick) were cut on positively charged slides, dewaxed in xylene, and hydrated in descending grades of ethanol. The endogenous peroxidase activity was quenched by incubation in 100% methanol with 3% hydrogen peroxide for 20 min. Antigen retrieval was performed by subjecting the sections in citrate buffer (pH 7.0) for 15 min in microwave at 700 W. Sections were incubated at room temperature in

a humid chamber with primary mouse monoclonal antibody against VEGF (DakoCytomation, Clone VG 1, Code No. M7273) for 30 min. The antibodies were diluted 1:50 in phosphate-buffered saline (PBS). After rinsing in PBS, the sections were incubated at room temperature for 20 min with EnVision™ system (ChemMate Dako). After a further wash in PBS, the slides were incubated with DAB solution (0.01% hydrogen peroxide in 0.05% diaminobenzidine-tetrahydrochloride). Sections were counter stained with Meyer's hematoxylin and dehydrated in ethanol prior to mounting. Liver sections with the primary antibody replaced with PBS served as negative controls, while colonic cancer sections served as VEGF-positive controls. The liver sections were examined using a Zeiss light microscope (Oberkochen, Germany). VEGF expression sites were examined intralobular in the periportal areas in hepatocytes, Kupffer cells and endothelial cells lining sinusoids and granuloma.^[18] Immunohistochemical staining of sections was evaluated without knowledge of data.

Statistical analysis

Data are expressed as mean \pm SD. Significance was assessed by Student's *t*-test. $P < 0.05$ was considered statistically significant. Data were processed using the SPSS 17.0 software package (SPSS, Chicago, IL, USA).

Results

HO-1 mRNA expression and HO activity in the studied groups

As seen in Figure 1a, HO-1 mRNA expression was increased in liver homogenates of *S. mansoni*-infected mice compared to normal mice. The increase in HO-1 expression levels were detected in the 8th week post-infection then significantly decreased in the 12th week post-infection but still significantly higher than normal mice [Figure 1b].

HO-1 activity as detected by percentage of COHb was increased in *S. mansoni*-infected mice compared to non-infected control group. This activity is declined at 12th week post-infection compared to the activity at 8th week post-infection [Table 1].

IL-4, IL-12, and VEGF serum levels in the studied groups

Significant elevation of serum IL-4 was observed in *S. mansoni*-infected mice at 8th and 12th weeks post-infection compared to non-infected control mice. However, IL-12 levels were significantly decreased in 8th and 12th weeks post-infection in infected mice compared to non-infected control mice. In addition, VEGF serum levels were significantly increased in

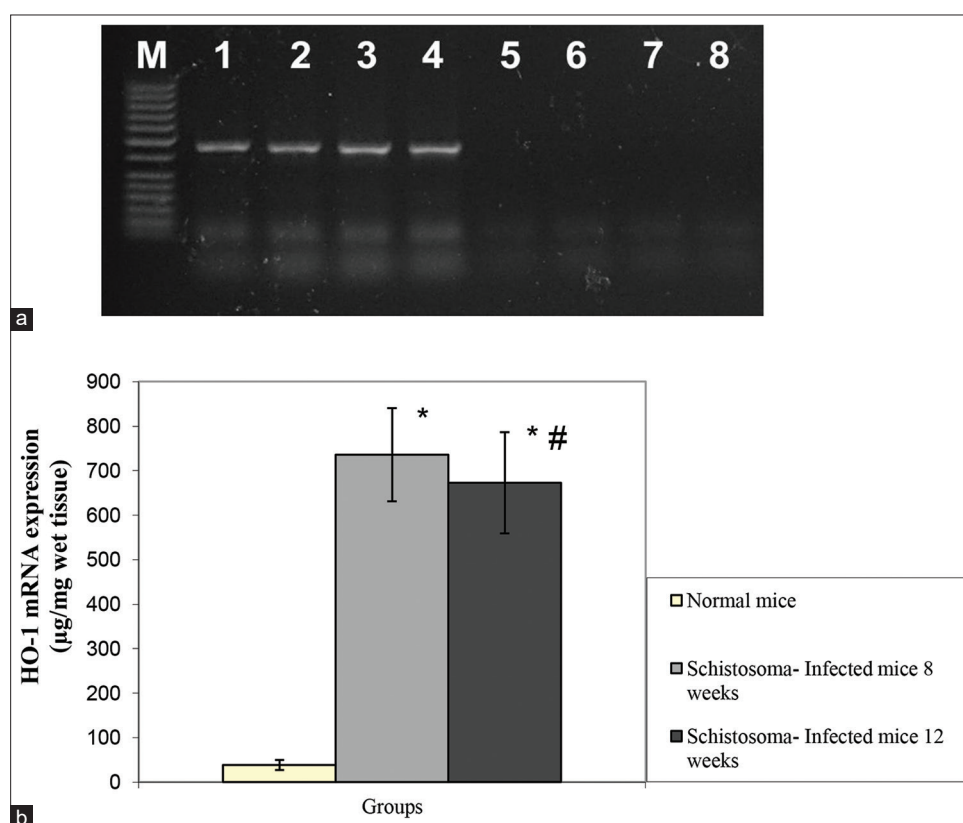


Figure 1: (a) Expression of HO-1 mRNA in the studied groups. M; 100 bp marker, lanes 1,2; *S. mansoni*-infected mice 8 weeks post-infection, lanes 3,4; *S. mansoni*-infected mice 12 weeks post infection, lanes 5, 6, 7, 8; non-infected control mice. (b) HO-1 mRNA expression ($\mu\text{g}/\text{mg}$ wet tissue) in the studied groups. Values are represented as mean \pm SD ($n=30$). *Significantly different from normal mice at $P < 0.05$. #Significantly different from *S. mansoni*-infected mice 8 weeks post-infection at $P < 0.05$

S. mansoni-infected mice at 8th and 12th weeks post-infection compared to non-infected control mice [Table 1].

Histological findings

Figure 2 shows histopathological picture of liver tissue from control mice [Figure 2a]. Sections from the liver 8th week post-infection Figure 2b) showed the presence of adult bilharzia worm in hepatic central vein surrounded by mild inflammatory reaction. The rest of liver tissue showed the presence of living bilharzia ova in portal areas surrounded by collections of inflammatory cells (neutrophils, eosinophils, and macrophages), the size of the inflammatory reaction ranged from 1/2 – 1 high power field. Sections from the liver 12th week post-infection [Figure 2c) showed marked inflammatory reaction in hepatic lobules in absence of bilharzia ova forming fibrocellular granulomas, the reaction is also formed of neutrophils, macrophages, and eosinophils. There is also focal infiltration of inflammatory cells around blood vessels.

Figure 3 revealed Masson trichrome staining of mice liver's. There is no fibrosis in portal areas or in hepatic lobules in non-infected control group [Figure 3a]. Fibrocellular granuloma around bilharzia ova was detected in liver of 8th week post-infection group [Figure 3b), while mild fibrosis in portal areas was detected in liver of 12th week post-infection group [Figure 3c).

Immunohistochemical aspects

As shown in Figure 4, the control non-infected mice were negative for VEGF monoclonal antibodies [Figure 4a). Immunostaining for VEGF showed moderate staining in endothelial cells lining vessels and sinusoids 12 weeks post-infection [Figure 4c) in comparison to weaker staining 8 weeks post-infection [Figure 4b).

Discussion

Among tropical diseases, *S. mansoni* is the second major cause of morbidity and mortality worldwide.^[19]

HO-1 is a cytoprotective enzyme, the expression of which is highly sensitive to induction by pro-oxidant stimuli including the substrate heme and nitric oxide.^[20] This study showed that HO-1 mRNA expression together with HO activity was

significantly higher in mice infected with *S. mansoni* compared to non-infected mice, also HO-1 activity was declined in chronic stage compared to acute stage of schistosomiasis. Our findings were in agreement with the results reported by Aziz *et al.*^[21] The possible explanation of these results may be the fact that iron is used by schistosomes for development and reproduction and the use of iron was abundant in the stage of egg deposition. Roles of this abundant egg-associated iron use include early embryogenesis and stabilization of cross-linked proteins in eggshell formation.^[22] In agreement with this explanation, Maines and Senft reported that schistosome adult worm catabolizes hemoglobin to heme which is the powerful inducer of HO-1 gene expression.^[23]

VEGF is a major player in angiogenesis. Enhancement of VEGF expression is mediated by inflammatory cytokines.^[24]

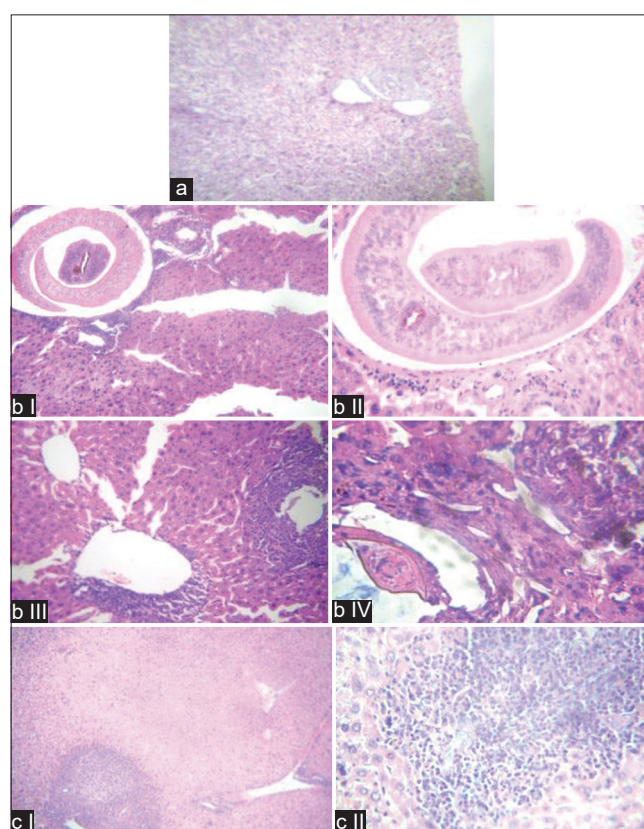


Figure 2: Hematoxylin and Eosin staining section of liver of the studied groups. (a) Liver control mice (H and E, ×100). (b) Histological section of liver of *S. mansoni*-infected mice (8 weeks). I; (H and E, ×100), II; (H and E, ×400) showed the presence of adult bilharzias worm in hepatic central vein surrounded by mild inflammatory reaction. III; (H and E, ×100), IV; (H and E, ×400) showed the presence of living bilharzia ova in portal areas surrounded by collections of inflammatory cells forming granulomas (neutrophils, eosinophils, and macrophages). The inflammatory reaction is multiple affecting all portal areas and is variable in size. (c) Histological section of liver of *S. mansoni*-infected mice (12 weeks). I; (H and E, ×100), II; (H and E, ×400) showed marked inflammatory reaction in hepatic lobules forming fibrocellular granulomas, bilharzia ova are fewer in number than that after 8 weeks. The reaction is also formed of neutrophils macrophages and eosinophils. There is also focal infiltration of inflammatory cells around blood vessels

Table 1: Serum IL-4 (pg/ml), IL-12 (pg/ml), COHb (%), and VEGF in normal and *Schistosoma*-infected mice groups

Groups	Normal mice	<i>Schistosoma</i> -infected mice	
		8 weeks	12 weeks
IL-4 (pg/ml)	71.25±14.8	196.75±32*	214.1±39.5*
IL-12 (pg/ml)	434.33±95.7	202±42.5*	182.8±60.5*
COHb (%)	0.79±0.02	1.6±0.104*	1.4±0.41*
VEGF (pg/ml)	36.8±8.48	70.12±19.63*	78.0±19.4*

Data are represented as mean±SD and analyzed using Student's *t*-test. *Significantly difference from normal mice at *P*<0.05. IL-4: Interleukin-4, IL-12: Interleukin-12, COHb: Carboxyhemoglobin, VEGF: Vascular endothelial growth factor

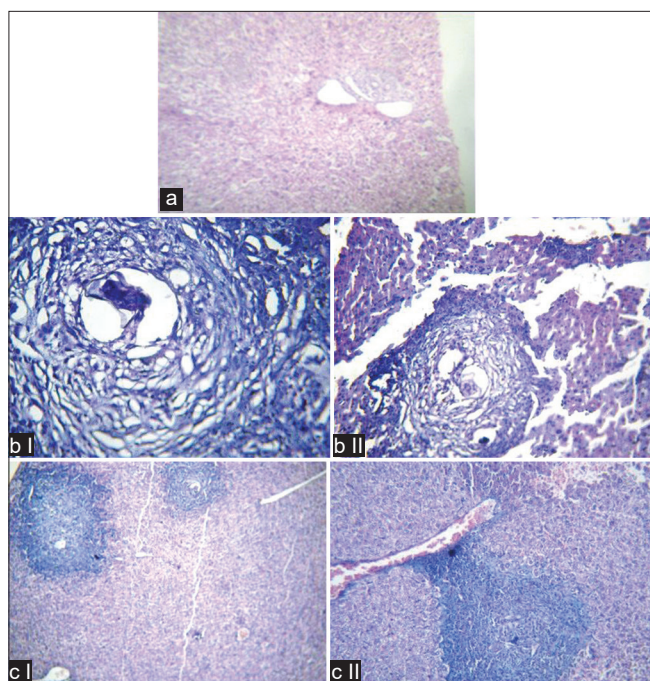


Figure 3: Masson trichrome staining section of liver of the studied groups. (a) Masson trichrome ($\times 100$) control section, no fibrosis in portal areas or in hepatic lobules. (b) Histological section of liver of *S. mansoni*-infected mice (8 weeks). I; ($\times 100$), II; ($\times 400$) showed the fibrocellular granuloma around bilharzia ova. (c) Histological section of liver of *S. mansoni*-infected mice (12 weeks). I; ($\times 100$), II; ($\times 400$) showed mild fibrosis in portal areas

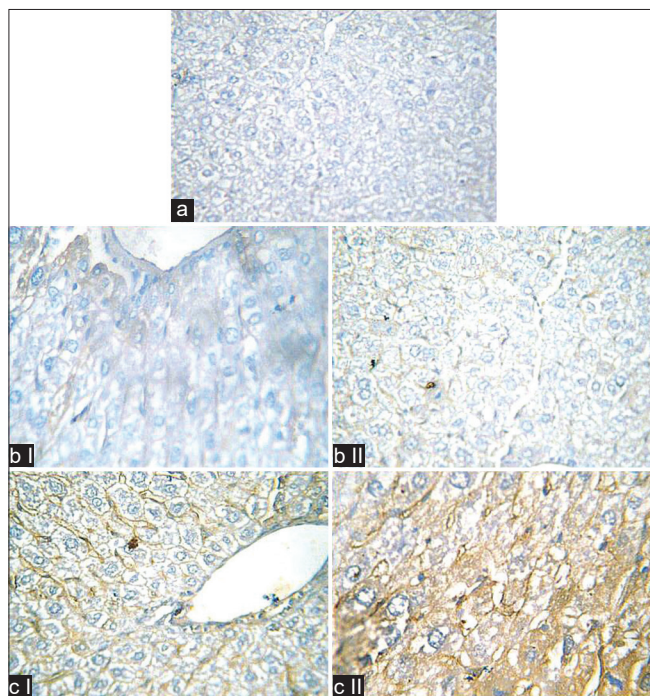


Figure 4: VEGF immunostaining in the studied groups. (a) Negative staining in control section, ($\times 100$). (b) 8 weeks post-infection liver section, I; (400), II; ($\times 100$) faint cytoplasmic and membranous staining in hepatocytes and cells lining the sinusoids. (c) 12 weeks post-infection liver section, I; (400), II; ($\times 100$) moderate cytoplasmic and membranous staining in hepatocytes and cells lining the sinusoids

In addition, HO-1 stimulates VEGF synthesis and cytokines expression.^[7] Therefore, the role of VEGF in the pathogenesis of *S. mansoni* infection was investigated in the present study. Serum level of VEGF was significantly raised in mice infected with *S. mansoni* compared to control group and this was agreed with the results of Tawfeek *et al.* and Shariati *et al.*^[25,26] Moreover, the level of VEGF was progressively increased in chronic stage at 12th week post-infection and the immunohistochemical staining in endothelial cells of liver biopsies from infected mice confirmed these results. Our findings suggested that VEGF may serve as a new indicator of progression of *S. mansoni* associated angiogenesis which regulates granuloma and/or fibrosis development in the liver of infected mice.^[25] In addition, understanding the role of VEGF in pathogenesis of *S. mansoni* may provide a new pharmacological target.

Schistosomiasis is caused by the host reaction to parasite eggs which when trapped in tissues induce fibrotic granulomatous lesions that eventually impair organ function. Schistosome eggs are responsible for the development of Th2 immune response seen in patently infected animals.^[27] Th2 immune response is characterized by the increased production of type 2 cytokines IL-4.^[28] Our results showed a significant progressive elevation of IL-4 in *S. mansoni*-infected mice at 8th and 12th weeks post-infection compared to non-infected control mice and this was agreed with the results reported by Rolot and Dewals.^[29] The role of Th2 response manifested by elevated IL-4 during schistosoma remain contradictory. IL-4 has been determined as necessary factor for resistance to *S. mansoni* super infection in mice.^[30] Other studies, instead has viewed Th2 response as deleterious mediating sever pathology and promoting worm survival and fecundity.^[31] This may explain the elevation of IL-4 in both acute and chronic phases of schistosomiasis.

On the other hand, IL-12 may have potential use in preventing or treating parasite-induced pathology resulting from Th2 cytokine production. In the current study, IL-12 levels were significantly decreased in acute and chronic infection with *S. mansoni* which may explain the progression of fibrosis that follows the inflammatory process during the chronic phase and this was agreed with Wynn *et al.*^[32] The previous report showed that IL-12 enhances protective immunity in mice engendered by immunization with recombinant *S. mansoni* fatty acid-binding protein as reduction of hepatic granuloma area was only observed when IL-12 was coadminstrated with the vaccine.^[33]

Conclusion

Our results confirmed the role of cytokines in the evolution and regulation of schistosoma-induced immunopathology. Moreover, our data suggested that the body response to *S. mansoni* infection by elevating the expression of the stress gene HO-1 and that VEGF may serve as a new indicator of progression of *S. mansoni* associated angiogenesis which regulates granuloma and/or fibrosis development in the liver

of infected mice. Understanding the role of HO-1 and VEGF in pathogenesis of *S. mansoni* may provide a new pharmacological target in therapeutic management of schistosomiasis.

Authors' Declaration Statements

Ethics approval

All experimental protocols were approved by the Ethics Committee at the Faculty of Pharmacy, Suez Canal University (Ismailia, Egypt) (code # 201906RA1).

Availability of data and material

Not applicable

Competing interests

The authors declare that there are no conflicts of interest.

Funding statement

This work was funded by King Abdulaziz University.

Authors' Contributions

All authors contributed in the design of the study. All authors participated in data collection and analysis, data interpretation, and manuscript writing.

Acknowledgment

The authors acknowledge King Abdulaziz University, Jeddah, for scientific research.

ORCID link of the corresponding author: 0000-0003-2951-6046

References

- Bergquist NR, Colley DG. Schistosomiasis vaccines: Research to development. *Parasitol Today* 1998;14:99-104.
- Ferrari ML, Coelho PM, Antunes CM, Tavares CA, da Cunha AS. Efficacy of oxamniquine and praziquantel in the treatment of *Schistosoma mansoni* infection: A controlled trial. *Bull World Health Organ* 2003;81:190-6.
- Abo-Madyan AA, Morsy TA, Motawea SM. Efficacy of myrrh in the treatment of schistosomiasis (*Haematobium* and *Mansoni*) in Ezbet El-Bakly, Tamyia Center, El-Fayoum Governorate, Egypt. *J Egypt Soc Parasitol* 2004;34:423-46.
- Ghatts MH, Chuang LT, Kappas A, Abraham NG. Protective effect of HO-1 against oxidative stress in human hepatoma cell line (HepG2) is independent of telomerase enzyme activity. *Int J Biochem Cell Biol* 2002;34:1619-28.
- Quan S, Yang L, Abraham NG, Kappas A. Regulation of human heme oxygenase in endothelial cells by using sense and antisense retroviral constructs. *Proc Natl Acad Sci U S A* 2001;98:12203-8.
- Malaguamera L, Pilastro MR, Quan S, Ghatts MH, Yang L, Mezentsev AV, *et al.* Significance of heme oxygenase in prolactin-mediated cell proliferation and angiogenesis in human endothelial cells. *Int J Mol Med* 2002;10:433-40.
- Abdel-Aziz MT, El-Asmar MF, El-Miligy D, Atta H, Shaker O, Ghatts MH, *et al.* Retrovirus-mediated human heme oxygenase-1 (HO-1) gene transfer into rat endothelial cells: The effect of HO-1 inducers on the expression of cytokines. *Int J Biochem Cell Biol* 2003;35:324-32.
- Baptista AP, Andrade ZA. Angiogenesis and schistosomal granuloma formation. *Mem Inst Oswaldo Cruz* 2005;100:183-5.
- Loeffler DA, Lundy SK, Singh KP, Gerard HC, Hudson AP, Boros DL. Soluble egg antigen from *Schistosoma mansoni* induce angiogenesis-related processes by up-regulating vascular endothelial growth factor in human endothelial cells. *J Infect Dis* 2002;185:1650-6.
- Berger A. Th1 and Th2 responses: What are they? *BMJ* 2000;321:424.
- Othman AA, Shoheib ZS, Saied EM, Soliman RH. Congenital exposure to *Schistosoma mansoni* infection: Impact on the future immune response and disease outcome. *Immunobiology* 2010;215:101-12.
- Fonseca CT, Pacifico LG, Barsante MM, Rassi T, Cassali GD, Oliveira SC. Co-administration of plasmid expressing IL-12 with 14kDa *Schistosoma mansoni* fatty acid binding protein cDNA alters immune response profiles and fails to enhance protection induced by Sm14DNA vaccine alone. *Microbes Infect* 2006;8:2509-16.
- Liang YS, Bruce JI, Boy DA. Laboratory cultivation of schistosome vector snails and maintenance of schistosome life cycles. In: *Proceedings First Sino American Symptom*. Berlin: ScienceOpen, Inc.; 1987. p. 34-48.
- Pacheco RG, Lenzi HL. Systemic modulation of peripheral eosinophilia (air pouch model) in *Schistosoma mansoni* infection. *Mem Inst Oswaldo Cruz* 1997;92:165-72.
- Zager RA, Johnson AC, Hanson SY. Parenteral iron nephrotoxicity: Potential mechanisms and consequence. *Kidney Int* 2004;66:144-56.
- Hampson NB, Scott KL, Zmaeff JL. Carboxyhemoglobin measurement by hospital: Implications for the diagnosis of carbon monoxide poisoning. *J Emerg Med* 2006;31:13-6.
- Mahmoud TY, Rizk SM, Maghraby AS, Shaheen AA. Propolis enhances the effectiveness of praziquantel in experimental schistosomiasis: Biochemical and histopathological study. *Parasitol Res* 2014;113:4513-23.
- Botros SS, Hammam O, Mahmoud M, Berquist R. Praziquantel efficacy in mice infected with PZQ non-susceptible *S. mansoni* isolate treated with artemether: Parasitological, biochemical and immunohistochemical assessment. *APMIS* 2010;118:692-702.
- Facundo HT, Brandt CT, Owen JS, Lima VL. Elevated levels of erythrocyte-conjugated dienes indicate increased lipid peroxidation in schistosomiasis *Mansoni* patients. *Braz J Med Biol Res* 2004;37:957-62.
- Naughton P, Hoque M, Green CJ, Foresti R, Motterlini R. Interaction of heme with nitroxyl or nitric oxide amplifies heme oxygenase-1 induction: Involvement of the transcription factor Nrf2. *Cell Mol Biol* 2002;48:885-94.
- Aziz MT, El-Asmar MF, Atta HM, Nassar YH, Shaker OG, Abd El-Fattah MM, *et al.* Gene expression of heme oxygenase-1: Relationship to fibrogenic and apoptotic factors in murine schistosomiasis. *J Clin Biochem Nutr* 2005;36:67-78.
- Glanfield A, McManus DP, Anderson GJ, Jones MK. Pumping iron: A potential target for novel therapeutics against schistosomes. *Trends Parasitol* 2007;23:583-8.
- Maines MD, Senft AW. Host heme biosynthesis and degradation in schistosomiasis. *Am J Trop Med Hyg* 1981;30:1010-9.
- Carmeliet P. Mechanisms of angiogenesis and arteriogenesis. *Nat Med* 2000;6:389-95.
- Tawfeek GM, Alahifi AM, Azmy MF. Immunological indicators of morbidity in human Schistosomiasis *mansoni*: Role of vascular endothelial growth factor and anti-soluble egg antigen IgG4 in disease

- progression. *J Egypt Soc Parasitol* 2003;33:597-614.
26. Shariati F, Perez-Arellano JL, Carranza C, Lopez-Aban J, Vicente B, Arefi M, *et al.* Evaluation of the role of angiogenic factors in the pathogenesis of schistosomiasis. *Exp Parasitol* 2011;128:44-9.
 27. Oswald IP, Caspar P, Jankovic D, Wynn TA, Pearce EJ, Sher A. IL-12 inhibits Th2 cytokine responses induced by eggs of *Schistosoma mansoni*. *J Immunol* 1994;153:1707-13.
 28. Pearce EJ, Caspar P, Grzych JM, Lewis FA, Sher A. Downregulation of Th1 cytokine production accompanies induction of Th2 responses by a parasitic helminth, *Schistosoma mansoni*. *J Exp Med* 1991;173:159-66.
 29. Rolot M, Dewals BG. Macrophage activation and functions during helminth infection: Recent advances from the laboratory mouse. *J Immunol Res* 2018;2018:17.
 30. Brunet LR, Kopf MA, Pearce EJ. *Schistosoma mansoni*: IL-4 is necessary for concomitant immunity in mice. *J Parasitol* 1999;85:734-6.
 31. Amiri P, Haak-Frendscho M, Robbins K, McKerrow JH, Stewart T, Jardieu P. Anti-immunoglobulin E treatment decreases worm burden and egg production in *Schistosoma mansoni* infected normal and interferon gamma knockout mice. *J Exp Med* 1994;180:43-51.
 32. Wynn TA, Cheever AW, Jankovic D, Poindexter RW, Caspar P, Lewis FA, *et al.* An IL-12-based vaccination method for preventing fibrosis induced by schistosome infection. *Nature* 1995;376:594-6.
 33. Fonseca CT, Brito CF, Alves JB, Oliveira SC. IL-12 enhances protective immunity in mice engendered by immunization with recombinant 14kDa *Schistosoma mansoni* fatty acid-binding protein through an IFN-gamma and TNF-alpha dependent pathway. *Vaccine* 2004;22:503-10.