

Acantholytic squamous cell carcinoma arising in a nevus sebaceous: A case report

Ahmed Alhumidi, MD

Assistant Professor and Consultant of Histopathology and Dermatopathology
King Khalid University hospital
King Saud University
P.O. Box 2925, Riyadh – 11461
Department of Pathology (32)
Riyadh
Kingdom of Saudi Arabia

Abstract

Although nevus sebaceous (NS) is known to develop various types of secondary neoplasms, it rarely causes carcinoma and only fifteen cases of secondary squamous cell carcinoma (SCC) have been reported. We report a rare variant of SCC (acantholytic type) arising in nevus sebaceous.

Key words:

Nevus sebaceous, squamous cell carcinoma, tumors

Correspondence:

Dr Ahmed Alhumidi, MD

Assistant Professor and Consultant of Histopathology and Dermatopathology
King Khalid University hospital
King Saud University
P.O. Box 2925, Riyadh – 11461
Department of Pathology (32)
Riyadh
Kingdom of Saudi Arabia
Email: ahmedbgj@hotmail.com

Introduction:

Nevus sebaceus of Jadassohn is a complex hamartoma involving pilosebaceous unit, epidermis and other adnexal structures. It is usually involving the scalp or the face. A wide variety of benign and malignant tumors have been described in association with nevus sebaceous. ⁽¹⁾ The most common benign tumors are trichoblastoma. ⁽²⁾ The proportion of malignant tumors occurring on NS is highly variable among the published series. Amongst malignant tumors, the most common is basal cell carcinoma. Squamous cell carcinoma has been rarely reported with nevus sebaceous. ⁽³⁾

Objectives:

The objective was to report the case of a patient with a nevus sebaceus that a rare variant of squamous cell carcinoma. The pathologist should be aware of tumors arises in nevus sebaceous, especially malignant ones.

Case report:

An 80-year-old male presented with a nodule arising over his nose for six months duration. Clinical examination revealed that his left nasal skin had a nodular surface in which a larger erythematous firm nodule measured 1.5 × 1 cm was noted. The patient had no personal or family history of cutaneous or internal malignancies. The clinical impression was rhinophyma with a tumor. An incisional biopsy was done and reported as atypical acantholytic squamous cells. Another larger biopsy was recommended. Subsequently, wide local excision was performed.

Microscopically, the tumor consisted of lobules and nests of focally keratinizing, atypical, squamous epithelial cells (Figure-1). Approximately 60 % of the tumor showed acantholytic changes and acantholysis was equally distributed through the entire tumor. Tumor cells were large with bright eosinophilic, focally glassy cytoplasm and vesicular nuclei with small to medium sized nucleoli (Figure 2). The skin around this tumor showed abnormal location of sebaceous glands which opened directly to skin surface (Figure 1). The hair follicles were small and abortive (Figure 3). The final diagnosis was acantholytic squamous cell carcinoma arising in a background of nevus sebaceous.

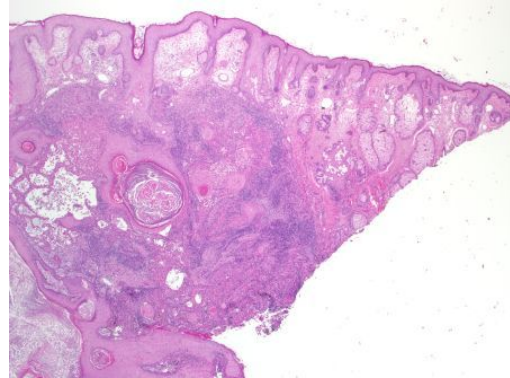


Figure 1. A dermal proliferation of squamous cells with central keratinization (H/E ×20).

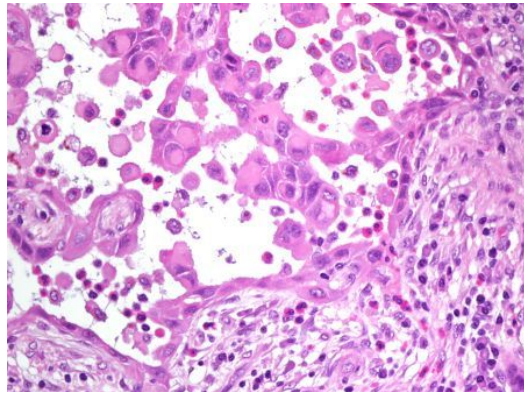


Figure 2. Acantholytic changes of tumor cells that reveal large with bright eosinophilic, focally glassy cytoplasm and vesicular nuclei with small to medium sized nucleoli (H/E ×400).

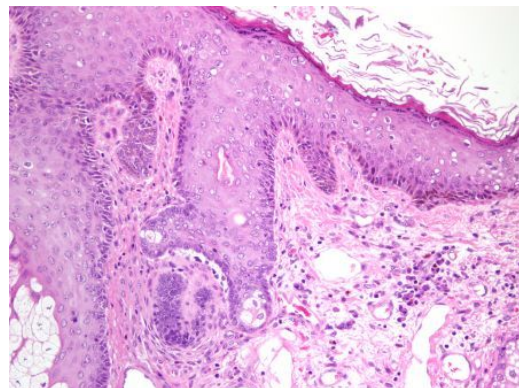


Figure 3. Skin surface around the tumor shows sebaceous gland opens directly to the surface. The hair follicle is small and abortive (H/E ×400).

Discussion

Nevus sebaceous (NS) is a hamartomatous skin malformation present in 0.3% of newborns. ⁽⁴⁾ Clinically, it appears as a pink-orange-yellowish, linear or oval, slightly elevated plaque, several centimeters in size, with a waxy aspect and a soft, velvety surface. During puberty, the lesion becomes thicker and verrucous. Histopathologic characteristics of NS are epithelial hyperplasia and papillomatosis, ectopic apocrine glands, and mature hypoplastic or superficially located sebaceous glands. Apocrine and sebaceous changes appear at puberty. ⁽⁵⁾

Various tumors have been reported in association with NS. In a study done by Cribier et al, a total of 596 of NS cases were studied. Basal cell carcinomas were found in 5 cases, and benign tumors in 81 cases. Syringocystadenoma papilliferum (30 cases) and trichoblastoma (28 cases) were the most frequent benign tumors. ⁽⁶⁾ Other types of benign neoplasms are trichilemmoma, sebaceoma, seborrheic keratosis, syringoma, poroma, nodular hidradenoma, apocrine cystadenoma, and nonepithelial proliferations such as melanocytic nevi. ⁽⁷⁾

The true incidence of malignant tumors occurring in lesions of NS is difficult to determine. In a review study done by Megan N, the most common malignancy observed was BCC. The next most common malignancy was sebaceous carcinoma, followed by squamous cell carcinoma and keratoacanthoma (KA). Other tumors observed included melanoma, porocarcinoma, adnexal carcinoma or adenocarcinoma, apocrine carcinoma, and leiomyosarcoma. Occasionally, more than one malignant lesion occurred in the same NS. Tumors observed together included BCC with SCC, sebaceous carcinoma, or KA and SCC with adnexal carcinoma. ^(3, 8, 9, 10) Our case is very rare variant of SCC (acantholytic) that has not been reported to date arising in nevus sebaceous.

Acantholytic squamous cell carcinoma (SCC) is a rare variant of squamous cell carcinoma and few cases have been reported in literature. Initially this tumor was considered to have a sweat gland origin by Lever in 1947 and was called Adenoid acanthoma of sweat gland. ⁽¹¹⁾ However, later it was accepted as an uncommon variant of squamous cell carcinoma. ^(12, 13) Many of the tumor strands

may show tubular and alveolar formations, which are referred to as pseudoglandular appendages. These spaces contain acantholytic cells that result from loss of cohesion of the tumor cells. ⁽¹³⁾ To the best of our knowledge, this is the first acantholytic SCC arising in nevus sebaceous.

In conclusion, the development of a nodule on NS in many cases represents a benign appendageal tumor. However, malignant conversion should be suspected with the appearance of a rapidly growing circumscribed or ulcerated lesion within the NS, and an early excision of this type of lesion is recommended.

References:

1. Kaddu S, Schaeppi H, Kerl H, Soyer HP. Basaloid neoplasms in nevus sebaceous. *J Cutan Pathol* 2000;27:327-37
2. Cribier B, Scrivener Y, Grosshans E. Tumors arising in nevus sebaceous: A study of 596 cases. *J Am Acad Dermatol* 2000;42:263-8
3. Moody, M. N., Landau, J. M. and Goldberg, L. H. (2011), Nevus Sebaceous Revisited. *Pediatric Dermatology*. doi: 10.1111/j.1525-1470.2011.01562.
4. Stavrianeas NG, Katoulis AC, Stratigeas NP, et al. Development of multiple tumors in a sebaceous nevus of Jadassohn. *Dermatology* 1997; 195:155–8.
5. Bourrat E, Rybojad M. Hamartome sébacé. *Ann Dermatol Venereol* 2003; 130:1068–71.
6. Cribier B, Scrivener Y, Grosshans E, Tumors arising in nevus sebaceous: A study of 596 cases. *J Am Acad Dermatol*.2000 Feb; 42(2 Pt 1):263-8.
7. Aguayo R, Pallarés J, Casanova JM et al. Squamous cell carcinoma developing in Jadassohn's sebaceous nevus: case report and review of the literature. *Dermatol Surg* 2010; 36:1763–1768.
8. Aguayo R, Pallarés J, Casanova JM. Squamous cell carcinoma developing in Jadassohn's sebaceous nevus: case report and review of the literature. *Dermatol Surg*. 2010 Nov; 36(11):1763-8.
9. Arshad AR, Azman WS, Kreetharan A. Solitary sebaceous nevus of Jadassohn complicated by squamous cell carcinoma and basal cell carcinoma. *Head Neck*. 2008 Apr; 30(4):544-8.

10. Izumi M, Tang X, Chiu CS, Nagai T. Ten cases of sebaceous carcinoma arising in nevus sebaceus. *J Dermatol.* 2008 Nov; 35(11):704-11.
11. Takagi M, Sakota Y, Takayama Set al. Adenoid squamous cell carcinoma of the oral mucosa. *Cancer*, 1977; 40:2250-55.
12. Toyoma K, Hashimoto K, Tagami H. Acantholytic squamous cell carcinoma involving the dorsum of foot of elderly Japanese Br, *J. Dermatol.*, 1995;133:141-54.
13. Lever WF, Schaumburg - Iver G. *Histopathology of the skin*, 7th edn., Philadelphia, JB LippincottCo., 1989. pp. 556-57.