

# Use of fibular bone graft and cancellous screw fixation in the management of neglected femur neck fractures in young patients

Ghulam Mustafa Kaim Khani<sup>1</sup>,  
Kamran Hafeez<sup>2</sup>,  
Muhammad Bux<sup>3</sup>,  
Nusrat Rasheed<sup>1</sup>,  
Naveed Ahmed<sup>4</sup>,  
M. Perwez Anjum<sup>1</sup>

<sup>1</sup>Department of Orthopaedics, Dow International Medical College, Dow University of Health Sciences (Ojha Campus), Karachi, Pakistan, <sup>2</sup>Consultant Orthopaedic Surgeon, Buraidah Central Hospital, Buraidah, Al-Qaseem Region, Saudi Arabia, <sup>3</sup>Department of Orthopaedics, Lyari General Hospital, Karachi, Pakistan, <sup>4</sup>Department of Orthopaedics, Civil Hospital, Dow University of Health Sciences, Karachi, Pakistan

#### Address for correspondence:

Dr. Kamran Hafeez, Consultant Orthopaedic Surgeon, Buraidah Central Hospital, Buraidah, Al-Qaseem Region, Saudi Arabia.  
Phone: +966535853411.  
E-mail: kamranhafeez@hotmail.com

WEBSITE: ijhs.org.sa

ISSN: 1658-3639

PUBLISHER: Qassim University

## ABSTRACT

**Objective:** To present the clinical outcome of patients with neglected femur neck fracture treated with fibular bone graft.

**Methods:** During May 2010-February 2013, 15 patients younger than 35 years of age with neglected fracture neck of femur were managed with non-vascularized fibular graft and cannulated screws. Fractures were classified according to Sandhu Classification. Hip function was assessed using Harris hip score.

**Results:** Fifteen patients with mean age of 28.67 years were managed. Mean period of delay from injury to presentation was 3.07 months. Mean follow-up was 18.5 months. Union was achieved in 13 cases. 2 patients developed nonunion with progression of avascular necrosis (AVN). Patients with healed fracture did not show radiological signs of AVN till the past follow-up. Functional status was evaluated at 6 months according to Harris hip score and was poor in 2 patients, fair in 2 patients, good in 6 patients, and excellent in 5 patients.

**Conclusion:** Fibular graft along with two cancellous screws proved to be an effective technique in our cases with neglected femur neck fractures.

**Keywords:** Femur neck fractures, fibular graft, neglected fractures

## Introduction

Fracture neck of femur in young people is caused by high-energy trauma and treatment of these injuries remains nightmare for surgeons because of high incidence of avascular necrosis (AVN) of femoral head and nonunion of fracture. Due to precarious blood supply of femoral head, the incidence of AVN ranges from 0% to 67%.<sup>1</sup> Non-union in femoral neck fractures have been reported in as many as 43%<sup>2</sup> of the patients and up to 59% in one series.<sup>3</sup> As these fracture are intracapsular, presence of angiogenesis inhibiting factors in synovial fluid and absence of cambium layer is said to be responsible for nonunion.<sup>4</sup>

Neglected femur neck fractures in young people although rare in developed countries, are still seen in the developing countries. Poverty, poor health-care facilities in remote areas, treatment by traditional bone setters, and lack of education are contributing factors. There are no definite guidelines to define neglected fracture. Meyers *et al.*<sup>5</sup> defined neglected cases

as those seeking medical treatment after 4 weeks of injury while Sandhu *et al.*<sup>6</sup> defined it as 3 weeks after injury. For a successful union, the femoral head should be viable, with the size of the proximal fragment should be at least 2.5 cm long. Depending on viability of the femoral head, different treatment modalities have been devised for the treatment of this problem and preservation of femoral head in this age group remains priority.<sup>7-9</sup>

In our institution, we managed neglected cases of femur neck fractures with non-vascularized fibular graft along with cannulated screws due to the simplicity of the technique and no need for microvascular expertise. The aim of this study is to present the outcome of our cases.

## Methodology

This is a retrospective case series conducted in a Civil Hospital, Dow University of Health Sciences, Karachi, Pakistan. During May 2010-February 2013, patients younger than 35 years of

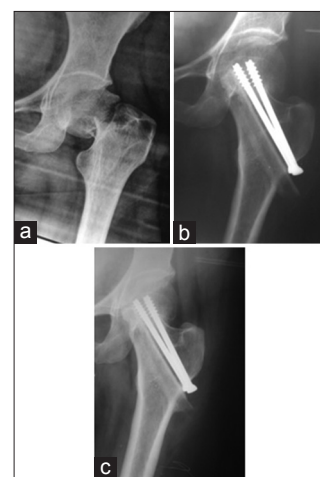
age presented with neglected (>3 weeks) fracture of femur neck were included in the study. All the patients with femoral neck fractures who were more than 35 years of age, who had associated injuries, who presented earlier than 3 weeks and with failed fixation of femur neck fractures were excluded from the study. There were 15 patients, 5 males and 10 females with age range of 19-35 years. Patients underwent detailed radiological assessment. Anteroposterior and lateral views were taken; and further evaluation with X-rays of hip joint in internal and external rotation to assess fracture comminution in posterior part of femoral neck, resorption of neck, and viability of femoral head. Viability of femoral head was further assessed with bone scan. Fractures were classified into 3 types according to Sandhu<sup>6</sup> classification which incorporates length of the proximal segment, gap between fracture segments, roughness of the fracture ends, and evidence of AVN in the femoral head. Type I fracture has irregular fracture surfaces, size of proximal segment 2.5 cm or more, gap between fracture segments 1 cm or less and viable femur head. Type II fracture has smooth surfaces, size of proximal segment 2.5 cm or more, gap between fracture segments more than 1 cm but <2.5 cm, and with viable femur head. Type III fracture has smooth surfaces, size of proximal segments less than 2.5 cm, gap between segments more than 2.5 cm, and with signs of AVN in femur head.

All operations were done on orthopedic traction table under image intensifier. Closed reduction was done in 7 cases, while in 8 cases open reduction was done through Watson-Jones approach. After reduction of fracture, under image intensifier guide wire passed and reamed with triple reamer of dynamic hip screw. Length measured and fibular graft of same length harvested from same side and inserted over the guide wire, then two cannulated cancellous screws of 6.5 mm size inserted, position checked in both anteroposterior and lateral views. Wound closed over redivac suction drain. Postoperatively, range of motion exercises started at hip joint. Patients were discharged once stable and pain-free. Patients were followed in outpatient clinic and stitches were removed on 12<sup>th</sup> post-operative day. Patients were followed monthly and X-rays were taken. Partial weight bearing was started after 6 weeks of surgery and full weight bearing was allowed once fracture was united. After union patients were followed in outpatient clinic after every 3<sup>rd</sup> month and fresh X-rays were taken for assessment of AVN, collapse of femoral neck, and screw or graft migration. Demographic data including age and gender were represented by mean and ratio, respectively. Hip function was assessed in each follow-up using Harris hip score.<sup>10</sup> Patients were informed and written consent was taken to include them in this study.

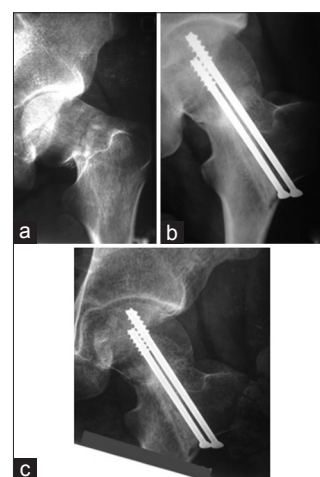
## Results

In this study, there were 15 patients who presented with neglected femur neck fractures and managed with fibular graft. Male-to-female ratio was 1:2, mean age was 28.67. 10 patients sustained fracture due to trauma and in 5 patients it was due

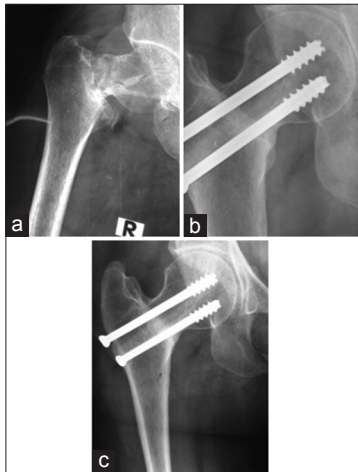
to metabolic (osteomalacia) disorder. According to Sandhu classification, 7 patients were Type I, 6 patients were Type II, and 2 patients were Type III. Mean period of delay from injury to presentation at our institute was 3.07 months (ranging from 1 to 6 months). Mean follow-up was 18.5 months (ranging from 10 to 49 months). Union was achieved in 13 cases during 3-5 months (average 3.7 months). 2 patients developed nonunion with progression of AVN (Sandhu Type III) which were later treated with bipolar hemiarthroplasty, both of these cases presented with history of trauma. None of our patients with healed fracture developed fracture of fibular graft and did not show signs of AVN in femoral head on X-rays till the past available follow-up. Functional status was evaluated at 6 months according to Harris hip score and was poor in 2 patients (Sandhu Type III), fair in 2 patients (Sandhu Type II), good in 6 patients (4 patients Sandhu Type II and 2 patients Sandhu Type I), and excellent in 5 patients (Sandhu Type I). X-rays of 3 patients are shown in Figures 1-3.



**Figure 1:** 28-year-old female with trauma. (a) 7-week-old displaced fracture of femur, neck (b) 7-month post-operative X-ray, (c) 22-month post-operative X-ray



**Figure 2:** 26-year-old male with trauma, (a) 10-week-old fracture of femur neck, (b) 8-month post-operative X-ray, (c) 18-month post-operative X-ray



**Figure 3:** 34-year-old female with trauma, (a) 5-week-old fracture of femur neck, (b) 12-month post-operative X-ray, (c) 49-month post-operative X-ray

## Discussion

Fracture neck of femur in adults always presented a difficult problem with high rates of nonunion and AVN. In our series of 15 neglected cases managed with non-vascularized fibula graft, we achieved union in 13 cases (86.6%). Functional Harris hip score was excellent (33.3%;  $n = 5$ ) or good (40%;  $n = 6$ ) in most of the patients.

The outcome of neglected femur neck fracture depends on duration of injury and presentation. Biological changes occurring at the fracture ends helps in deciding about the correct management option to achieve union and salvage of femoral head.<sup>11</sup> Various surgical methods such as Pauwels' osteotomy,<sup>12</sup> vascularized fibular graft,<sup>13</sup> free fibular graft<sup>8</sup> with internal fixation, and muscle pedicle bone graft<sup>14</sup> have been advocated for the management of neglected fracture neck of femur. Free vascularized periosteal grafts have also been used for the treatment of nonunion of femoral neck and avascular femoral head with excellent results.<sup>15</sup> Pauwels' valgus osteotomy, represents a masterly mechanical concept, with which not only healing of the nonunion but also leg length discrepancy, rotational, and angular deformity can be corrected at the same time. The biomechanical principle behind Valgus osteotomy is that it converts shearing forces into compressive forces by changing the fracture inclination and helps in fracture healing. Kumar *et al.*<sup>16</sup> utilized this intertrochanteric osteotomy with little modification in 50 cases and reported 90% union with AVN in two healed cases. Free vascularized fibula graft is more biological graft but technically more demanding and greater expertise is needed.<sup>17</sup>

The free fibular strut graft provides structural support and osteogenic environment. With the passage of time, it gets incorporated with the host bone; however, the time period in which it gets incorporated is not studied well in the literature.

In our study, we also observed incorporation of fibular grafts in some of our patients with longer follow-up.<sup>18</sup>

Azam *et al.*<sup>19</sup> reported their results of 28 neglected femur neck fractures managed with non-vascularized fibula graft. In their series, they achieved union in 25 patients with nonunion observed in 3 patients. The mean follow-up was 4.6 years. Pal *et al.*<sup>20</sup> utilized single or double fibular strut grafts along with cancellous screws in neglected femoral fractures. Mean follow-up was 3 years, 4 patients had nonunion and 3 developed AVN. In our study, out of 15 cases there were two cases of nonunion while our mean follow-up (18.5 months) was less.

Nagi *et al.*<sup>21</sup> utilized fibular graft for the management of 26 femur neck fractures, 16 being old (>3 weeks) while 10 new cases (<3 weeks). They achieved union in all except for one. 4 patients had changes of AVN initially which improved clinically and radiologically after the treatment. No new case was notified with AVN after the treatment. In our study, none of our patient with healed fracture developed AVN during post-operative follow-up. According to Nagi closed reduction was not possible after 3 weeks; however, in our study, we were able to reduce the fracture closely in 7 patients.

Osteosynthesis is not contraindicated in the presence of AVN,<sup>2</sup> as reaming while preparing the track for fibular graft actually decompresses the head and enhances vascular granulation tissue.<sup>22</sup> In the series of cases by Nagi *et al.*,<sup>21</sup> they actually reported clinical and radiological improvement in the cases with AVN after fibular grafting. However, in our study, we observe progression of AVN in two cases (Sandhu Type III) along with nonunion.

Harvesting the fibula may lead to some minor donor site morbidities such as ankle swelling and mild pain after walking long distance.<sup>23</sup> However, in our study, patients never complained of these symptoms.

Retrospective nature of the study and small number of patients were the limitations of our study. The simplicity of the technique without the need of microsurgical expertise has been an alternative solution for this complex problem.

## Conclusion

Fibular graft along with two cancellous screws proved to be an effective technique in our cases with neglected femur neck fractures. Fibular strut graft facilitates bone regeneration and subchondral placement prevents femoral head collapse. Preservation of femoral head allows young patients to squat and sit cross leg. Technically, procedure is less demanding and can be performed in remote hospitals where expertise with microvascular surgery is not available.

## References

- Roshan A, Ram S. The neglected femoral neck fracture in young adults: Review of a challenging problem. *Clin Med Res* 2008;6:33-9.
- Jackson M, Learmonth ID. The treatment of nonunion after intracapsular fracture of the proximal femur. *Clin Orthop Relat Res* 2002;399:119-28.
- Protzman RR, Burkhalter WE. Femoral-neck fractures in young adults. *J Bone Joint Surg Am* 1976;58:689-95.
- Kregor PJ. The effect of femoral neck fractures on femoral head blood flow. *Orthopedics* 1996;19:1031-6.
- Meyers MH, Harvey JP Jr, Moore TM. Treatment of displaced subcapital and transcervical fractures of the femoral neck by muscle-pedicle-bone graft and internal fixation. A preliminary report on one hundred and fifty cases. *J Bone Joint Surg Am* 1973;55:257-74.
- Sandhu HS, Sandhu PS, Kapoor A. Neglected fractured neck of the femur: A predictive classification and treatment by osteosynthesis. *Clin Orthop Relat Res* 2005;431:14-20.
- Florschutz AV, Langford JR, Haidukewych GJ, Koval KJ. Femoral neck fractures: Current management. *J Orthop Trauma* 2015;29:121-9.
- Nagi ON, Dhillon MS, Goni VG. Open reduction, internal fixation and fibular autografting for neglected fracture of the femoral neck. *J Bone Joint Surg Br* 1998;80:798-804.
- Bhuyan BK. Augmented osteosynthesis with tensor fascia latae muscle pedicle bone grafting in neglected femoral neck fracture. *Indian J Orthop* 2012;46:439-46.
- Harris WH. Traumatic arthritis of the hip after dislocation and acetabular fractures: Treatment by mold arthroplasty. An end-result study using a new method of result evaluation. *J Bone Joint Surg Am* 1969;51:737-55.
- Jain AK, Mukunth R, Srivastava A. Treatment of neglected femoral neck fracture. *Indian J Orthop* 2015;49:17-27.
- Ballmer FT, Ballmer PM, Baumgaertel F, Ganz R, Mast JW. Pauwels osteotomy for nonunions of the femoral neck. *Orthop Clin North Am* 1990;21:759-67.
- LeCroy CM, Rizzo M, Gunneson EE, Urbaniak JR. Free vascularised fibular bone grafting in the management of femoral neck nonunion in patients younger than fifty years. *J Orthop Trauma* 2002;16:464-72.
- Baksi DP. Internal fixation of ununited femoral neck fractures combined with muscle-pedicle bone grafting. *J Bone Joint Surg Br* 1986;68:239-45.
- Gupta A. The management of ununited fractures of the femoral neck using internal fixation and muscle pedicle periosteal grafting. *J Bone Joint Surg Br* 2007;89:1482-7.
- Kumar N, Kalra M. Evaluation of valgus intertrochanteric osteotomy in neglected fracture neck femur in young adults. *J Clin Orthop Trauma* 2013;4:53-7.
- Xie X, Zhang C, Jin D, Chen S, Gao Y. Free vascularised fibular graft for neglected femoral neck fractures in young adults. *Hip Int* 2012;22:319-23.
- Singh S, Kumar D, Kumar S. Long term results of fresh femoral neck fractures treated by cancellous screw and fibular autograft. *MOJ Orthop Rheumatol* 2014;1:00020.
- Azam MQ, Iraqi A, Sherwani M, Sabir AB, Abbas M, Asif N. Free fibular strut graft in neglected femoral neck fractures in adult. *Indian J Orthop* 2009;43:62-6.
- Pal CP, Kumar B, Dinkar KS, Singh P, Kumar H, Goyal RK. Fixation with cancellous screws and fibular strut grafts for neglected femoral neck fractures. *J Orthop Surg (Hong Kong)* 2014;22:181-5.
- Nagi ON, Gautam VK, Marya SK. Treatment of femoral neck fractures with a cancellous screw and fibular graft. *J Bone Joint Surg Br* 1986;68:387-91.
- Pauyo T, Drager J, Albers A, Harvey EJ. Management of femoral neck fractures in the young patient: A critical analysis review. *World J Orthop* 2014;5:204-17.
- Anderson AF, Green NE. Residual functional deficit after partial fibulectomy for bone graft. *Clin Orthop Relat Res* 1991;267:137-40.